

# 'One- Phase' Versus 'Two- Phase' Orthodontic Treatment in the Management of Angle's Class II Malocclusion: A Case Report Comparing Treatments of Two Biological Sisters.

Isiekwe GI<sup>a</sup>, Adekoya MN<sup>b</sup>, daCosta OO<sup>a</sup>

## Abstract

The objective of this study was to compare two different treatment protocols ('one phase' and 'two-phase' treatments) for the management of Angle's Class II Division I malocclusion, using the case reports of two biological sisters treated at the Lagos University Teaching Hospital (LUTH), Idi-araba, Lagos. A comparison was made of the orthodontic treatment of both sisters, aged 15 and 10 years, who presented at the Orthodontic Unit of the Child Dental Health Department of the LUTH Dental Clinic, in 2005 and 2008, respectively. On examination, they both had severe cases of Angles Class II Division I malocclusion, with overjets of 12mm and 13mm, respectively, and very deep bites. One-phase (delayed) orthodontic treatment, involving a two-unit extraction in the upper arch, with fixed appliance therapy and reinforced anchorage was chosen for the older sister; while for the younger sister, a two-phase (early) treatment plan was chosen. This involved the use of a functional appliance: the twin block of Clark, in the first phase and fixed appliance therapy in the second phase. The same clinicians treated both sisters. Active treatment duration lasted approximately 57months and 48months for the older and younger patients, respectively. Post-treatment overjets of 4mm and 3.5mm, respectively, with normal overbites, were obtained in both patients. One phase and two-phase treatment protocols can be successfully used in the management of Angles Class II Division I malocclusion. Each protocol has its advantages and limitations. However, a thorough patient assessment and selection is required for the best treatment outcome in each case.

**Keywords:** Angle's Class II malocclusion, One-phase, Two-Phase orthodontic treatment.

## Author Affiliations

<sup>a</sup> Department of Child Dental Health,  
Faculty of Dental Sciences,  
College of Medicine, University of Lagos/ Lagos  
University Teaching Hospital, Idi-Araba,  
Lagos, Nigeria.

<sup>b</sup> Lagos University Teaching Hospital, Idi-Araba,  
Lagos, Nigeria.

## Correspondence to:

Dr G.I Isiekwe  
Department of Child Dental Health,  
Faculty of Dental Sciences,  
College of Medicine, University of Lagos,  
Idi-araba, Lagos, Nigeria.  
Email: ikisiekwe@yahoo.com, iisiekwe@unilad.edu.ng

## Introduction

The optimal timing for treatment of children with Class II malocclusions remains controversial. Some clinicians believe strongly that beginning treatment in the mixed dentition before adolescence is advantageous, but others are convinced that early treatment is often a waste of time and resources.<sup>1</sup> Patients and practitioners seek treatments that provide excellent outcomes by simple and efficient methods.<sup>1</sup> daCosta and Utomi,<sup>2</sup> reported that 11.2% of the Orthodontic

patients seen at the Lagos University Teaching Hospital presented with Angles Class II malocclusion.

Two main schools of thought exist, with regard to the timing and choice of orthodontic treatment for children presenting with Angle's Class II Division I malocclusion. One school of thought advocates an early or 2-phase treatment, in which the first phase commences in the mixed dentition using appliances such as the twin block or other functional appliances to achieve growth modification, while a second phase of treatment commences in the permanent dentition using fixed appliance therapy.<sup>3</sup> The other school of thought advocates a 1- phase or delayed/late treatment in which treatment is delayed until the late mixed dentition or early permanent dentition, when fixed appliance therapy is used.<sup>4</sup>

Tulloch et al,<sup>1</sup> highlighted the fact that for children with Class II malocclusion, the debate is not really whether it can be corrected at various times during a child's development, because ample evidence from clinical practice suggests it usually can. Rather, the important questions are, firstly, if treatment started in the mixed dentition before adolescence, when followed by a second phase of treatment in the early permanent dentition during adolescence, provides superior results to single-phase treatment delayed until adolescence? Secondly whether there are enough additional

benefits for patients, parents and practitioners to justify the greater burden of 2-stage treatment.

Thus, the aim of this study was to compare both treatment protocols by comparing the treatment modalities and outcome of two biological sisters, who presented with Angle's Class II malocclusion and were treated by the authors at the Lagos University Teaching Hospital. This case report was carried out in accordance with the Helsinki Declaration and full informed consent was obtained from both sisters, prior to Using their photographs and treatment details in compiling this case report.

## Case Reports

The patients, two biological sisters of Pakistani origin, were aged 15 and 10 years respectively, on presentation at the Orthodontic Clinic of the Child Dental Health Department of the Lagos University Teaching Hospital Dental Clinic, in 2005 and 2008, respectively. Their medical histories showed no systemic diseases or developmental anomalies.

### Patient 1

She was 15 years old. Teeth present were all the adult teeth except the four wisdom teeth. She had a very convex facial profile, with a prominent mentolabial depression, which is common to patients with Class II malocclusion. On intra-oral examination, she had a full unit Angles Class II Division I malocclusion, on Skeletal pattern 2 complicated by an increased overjet of 13mm, a complete and very deep overbite, potentially competent lips (Jacksons Classification 1/0) and a mild lower labial segment crowding of about 3mm.

Cephalometric analysis confirmed a Class II skeletal relationship (ANB angle, 60), with marked mandibular retrognathism (SNB angle, 64) in comparison to the norms for Pakistanis<sup>5</sup> (Table 1). She also had markedly proclined upper central incisors (UI/FP, 1230) and retroclined lower incisors (LI/MP, 860).

Treatment objectives for her were, extraorally, to improve the facial appearance by achieving a less convex facial profile and improved lip competence. Intraorally, to maintain a full unit Class II molar relationship, while achieving a Class I canine relationship with a normal incisor relationship. This would involve reducing the increased overjet to normal and also achieving a normal overbite, as well as to unravel the mild crowding present in the lower labial segment.

The treatment plan chosen for the patient, based

on her clinical and cephalometric assessment was comprehensive fixed appliance therapy (using a preadjusted edgewise appliance, Roth 022 prescription) with a 2-unit extraction in the upper arch (of the upper first premolars) and reinforced anchorage with a Transpalatal arch.

Leveling and aligning was carried out with Nickel titanium wires 0.014 inches in diameter and subsequently stainless steel wires 0.016, 0.018, and 0.020 inches in diameter, in a progressive manner, at 6 weeks interval. Reverse curves were bent into these wires to reduce the deep bite. Space closure was carried out on 0.019 x 0.025 rectangular arch wires. Spaces in the upper labial segment were closed with an elastic chain, while active tie backs were used to close buccal segment spaces (Fig 2).

The total active treatment time was 57 months. Her treatment was unduly prolonged, due to the fact that during the course of treatment, she got admitted to a University in another city far from the hospital location and so could not keep up with her regular clinic appointments. Post-treatment retention was achieved with a Hawley's retainer.

Post-treatment results showed an improved facial profile, with a full unit Angles Class II Division I malocclusion, a Class I canine relationship; an overjet of 4mm and a complete and normal overbite (Fig 4). All the residual spaces in the upper arch were closed and the mild crowding in the lower labial segment was resolved. Post treatment cephalometric analysis also showed an improved skeletal and dental profile (Table 1).

### Patient 2.

She was 10 years, 7 months old. She was in late mixed dentition on presenting to the clinic. She also had a very convex facial profile with a prominent mentolabial depression. On intra-oral examination she had an asymmetric molar relationship, with an Angles Class II Division I malocclusion, subdivision left on Skeletal pattern II; complicated by a 12 mm overjet and an incomplete and increased overbite. She also had mild spacing of the upper labial segment (4 mm) and very mild crowding of the lower labial segment (1 mm). The upper and lower posterior segments were in normal alignment. With respect to the arch width, the upper arch was constricted, while the lower arch was normal; however, there were no crossbites. Both maxillary canines were mesio palatally rotated, and she had a lower midline shift to the right of 3 mm (Figure 2). The upper right first maxillary molar was carious. There was a history of a digit sucking habit, which

she stopped when she was 4 years old. The treatment objectives for her were similar to those for Patient 1, except that in this case a bilateral Class one molar relationship was targeted.

A 2-phase treatment plan was chosen for her, because she was still in mixed dentition and at a suitable age to commence myofunctional therapy. The first phase would involve the use of a functional appliance (Twin block of Clark) and the second phase: fixed appliance orthodontic therapy using a preadjusted edgewise appliance.

The patient wore the twin block appliance for one year (9 months of active treatment and three months of retention) during this period she wore the appliance 24 hours a day including during mealtimes. The Twin block appliance used was a removable appliance and the patient's compliance with appliance wear was good. The authors have previously reported the post-treatment findings observed after this first phase of treatment.<sup>6</sup>

The second phase of treatment was carried out using a Roth '022 prescription preadjusted edgewise appliance and commenced immediately after Phase 1 treatment. The treatment sequence and arch wire changes were similar to those for Patient 1. The total duration for Phase 2 treatment was 36 months and this was also unduly prolonged due to poor compliance with scheduled appointments. Post treatment retention was achieved with Hawley's retainers.

Post-treatment results showed an improved facial profile, Angles Class I molar relationship, a canine class I relationship; an overjet of 4.5mm and a complete and normal overbite. The midlines were however, not coincident, as a lower midline shift to the left of about 2mm was still present at the end of treatment(Fig 4). Post treatment cephalometric analysis also showed an improved skeletal and dental profile (Table 1).

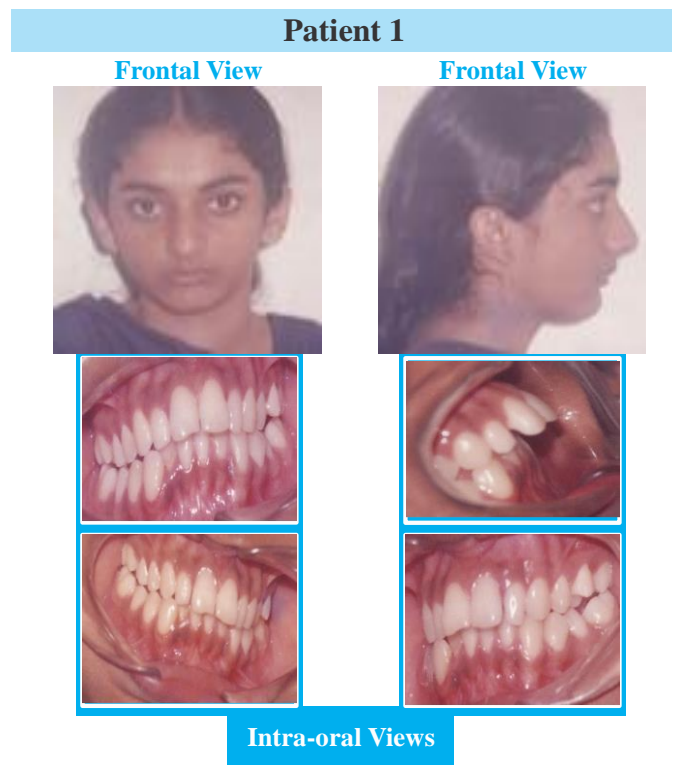
**Discussion**

The treatment of Class II malocclusions can be rendered by dentoalveolar changes, orthopedic forces to stimulate mandibular growth or inhibit maxillary growth, or surgical repositioning of the mandible in non-growing patients.<sup>7</sup> A lot of controversy exists in the management of children presenting with Class II division I malocclusion, with clinicians divided on whether one phase(late) or two-phase (early) treatment protocols provide a better treatment alternative. This study compared both treatment protocols in the treatment of two biological sisters presenting with Angles Class II

Division I malocclusion.

Tulloch et al,<sup>1</sup> in a study comparing 2-phase treatment of developing Class II malocclusions in patients with excessive overjets, with 1-phase treatment started in early permanent dentition, reported that there were few (if any) advantages when compared. The authors also reported that treatment results for both methods were quite similar, except that 1-phase treatment achieves the same objectives in a shorter time. Thus, in the conclusion of those authors, 1 phase treatment was more efficient for both patient and clinician. Another randomized clinical trial carried out by O'Brien and co-workers,<sup>8</sup> reported that early orthodontic treatment with the Twin block appliance followed by further treatment in adolescence at the appropriate time does not result in any meaningful long-term differences when compared with 1 course of treatment started in the late mixed or early permanent dentition. Their study further stated that there are definite disadvantages to the 2-phase treatment approach, including increased burdens for the patient in terms of attendance, costs and length of treatment. However, O'Brien et al,<sup>8</sup> in their study, reported limited advantages of the early treatment to include reduction in overjet, favourable, (but small) change in skeletal pattern and meaningful improvement in the self-esteem of the treatment group after the first phase of treatment.

Contrary to the reports by Tulloch et al,<sup>1</sup> and O'Brien et al, some other investigators have reported



CASE REPORT

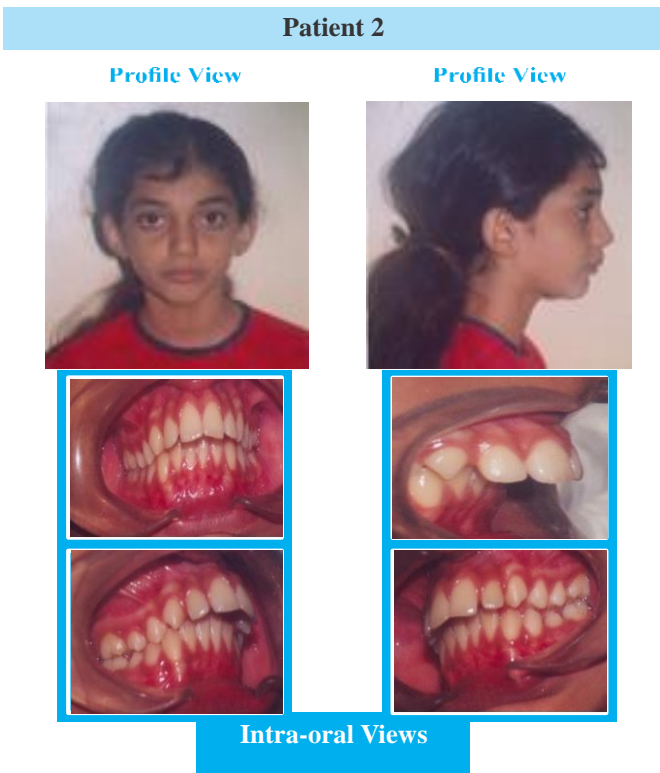

Figure 1: Pretreatment Photographs

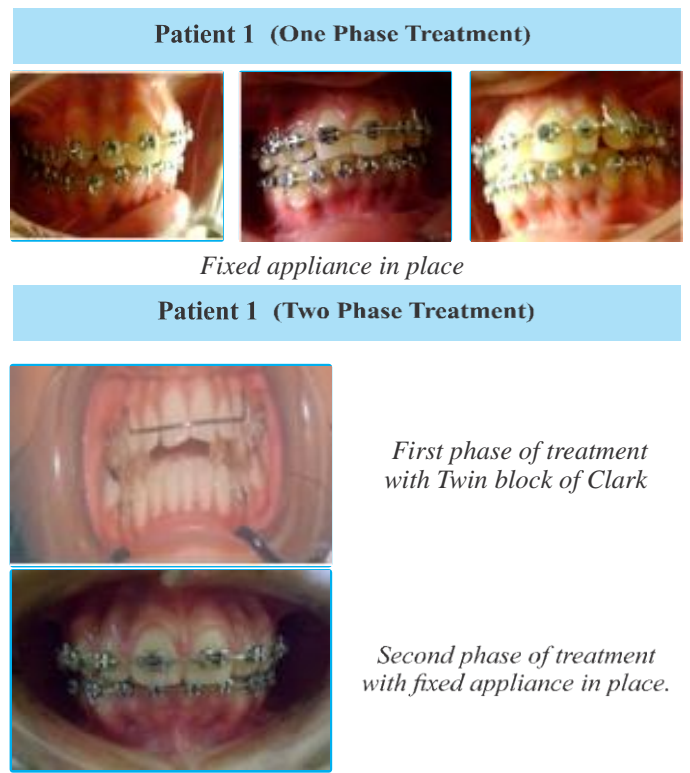


Figure 2: Intra - Treatment Photographs of both Patients

Table 1. Pre and Post-Treatment Cephalometric Analysis of both Sisters

Measurement Angular (degrees <sup>0</sup> )	Patient 1		Normal <sup>5</sup>	Patient 2	
	Pre-treatment	Post-treatment		Pre-treatment	Post-treatment
SNA	70.0	70.0	82.0	80.0	78.0
SNB	64.0	64.0	80.0	71.0	73.5
ANB	6.0	6.0	2-4	9.0	4.5
Upper Incisor to Frankfort plane A	123.0	107.0	111.5	127.0	106.0
Lower Incisor to Mandibular plane	86.0	103.0	95.4	106.0	110.0

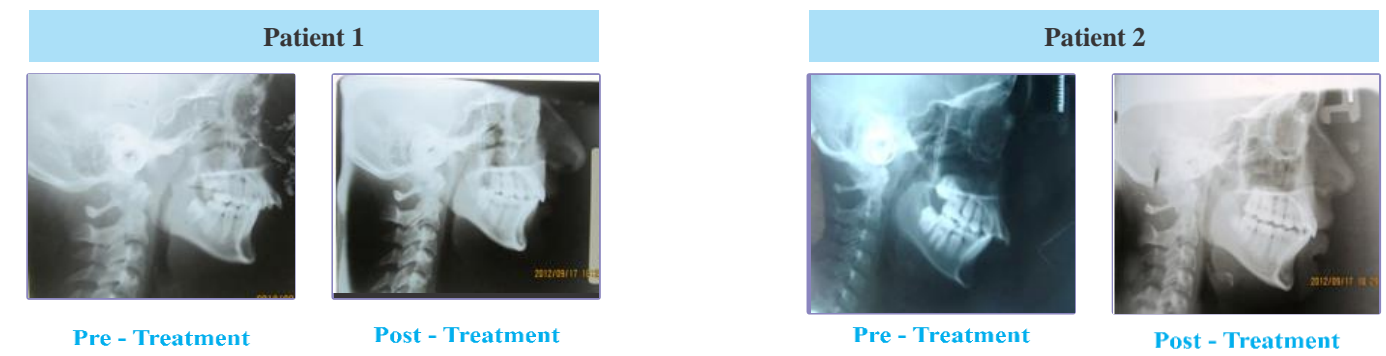


Figure 3: Pre and Post Treatment Cephalometric Radiographs of both Patients

CASE REPORT

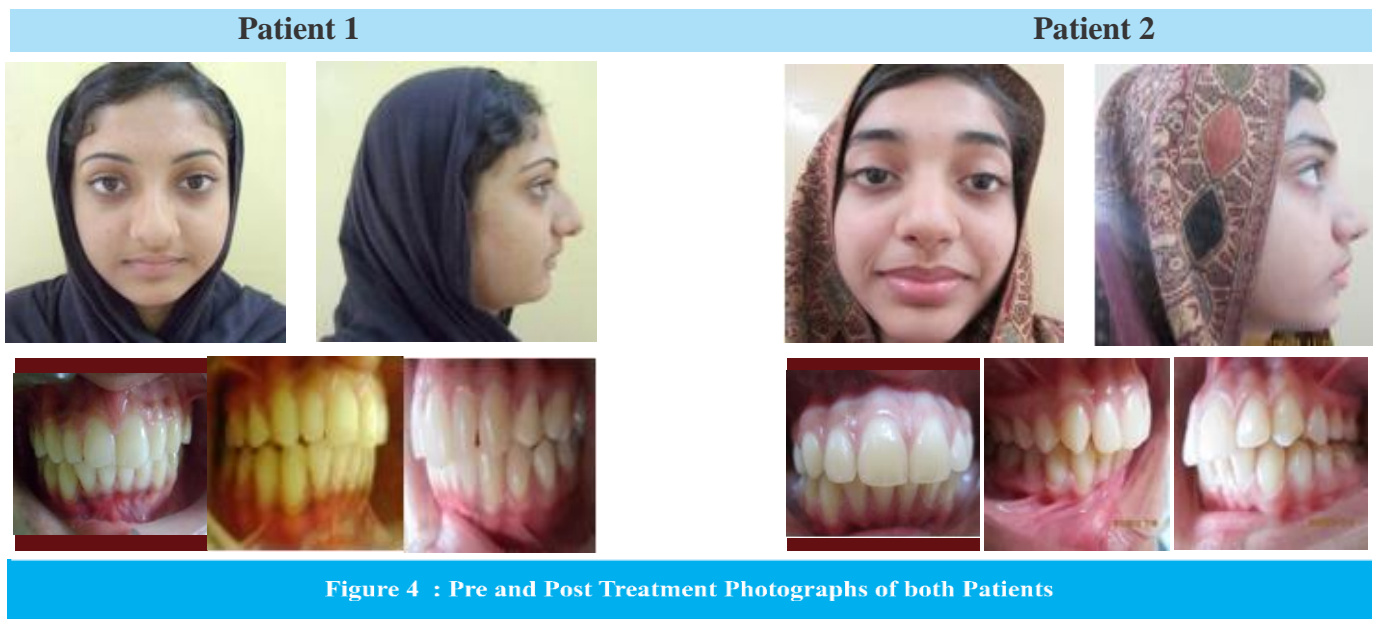


Figure 4 : Pre and Post Treatment Photographs of both Patients

that a 2-phase treatment plan offers greater advantages to the child; particularly with regard to external apical root resorption and incisal trauma.<sup>3,9,10</sup> Brin et al,<sup>9</sup> in a randomized clinical trial, reported that children who had 1-phase treatment had 2-4 times greater risk of developing External Apical Root Resorption (EARR) than did the 2-phase groups. Furthermore, they found significant associations between EARR, the magnitude of overjet reduction and the time spent wearing fixed appliances.<sup>9</sup> Segal et al,<sup>10</sup> in a meta-analysis to elucidate possible treatment-related etiologic factors for EARR, concluded that treatment-related causes of EARR appear to be the total distance the apex had moved and the time it took to accomplish the movement. Thus, if minimization of EARR is a goal of orthodontic treatment as it should be, clinicians must consider early treatment in the mixed dentition to modify growth and minimize residual tooth movement needed to correct the large overjets of patients having a 1-phase approach. However, one of the limitations of this study is that external apical root resorption was not assessed for both patients at the end of treatment, thus a comparison could not be made. Another important consideration raised by some authors is the issue of the magnitude of the overjet and incisal trauma (IT). Early orthodontic intervention aimed at reducing incisal trauma could save patients the monetary and psychological burdens of extended and complex dental treatments throughout life.<sup>3</sup> Thus, by starting treatment after the maxillary central incisors have erupted and following with a second phase of treatment at an appropriate time, the clinician can help minimize the incidence of both EARR and IT in Class II patients with large overjets.<sup>3</sup>

At the end of phase 1 treatment, Patient 2 had an improved skeletal and dental morphology. Similar findings have been reported in other studies.<sup>1,8</sup> In a previous report, the authors had highlighted the clinical and cephalometric changes that were observed in Patient 2 after the first phase of treatment.<sup>6</sup> The clinical changes included a reduction in overjet from 12mm to 4.5mm; achieving a normal overbite and an improvement in the patient's facial profile. Cephalometric changes included a slight reduction in the SNA angle from 80 to 78 and a slight increase in SNB angle from 71 to 72. Thus, there was a reduction in the ANB angle from 9 to 6. There was also a marked reduction in the maxillary incisor proclination, with respect to the Frankfort plane from 127 to 115 and a slight increase in mandibular incisor proclination by 1.5, from 106 to 107.5; with respect to the mandibular plane. Based on these changes, it may be argued that commencing treatment earlier or using a two-phase treatment plan in Patient 2, reduced the chances of incisal trauma in the child. It also played a great role in improving the child's self-confidence, due to the improved aesthetics observed after the phase of treatment. In addition, the use of a functional appliance in the first phase of treatment eliminated the need for a two-unit extraction, which was carried out in Patient<sup>2,6</sup>

This overjet reduction obtained in the second phase of treatment for patient 2 (1mm) compares favourably with the 1.5mm reported by Tulloch,<sup>1</sup> as often required in the second phase of treatment for children undergoing 2 phase appliance therapy. With respect to the molar relationship at the end of treatment, Patient 1 had a full unit Class II molar relationship with coincident midlines (Fig 4), while

Patient 2 had a Class I molar relationship with a lower midline shift to the right of about 2mm (Fig 4). This finding may be said to reinforce the report by O'Brien et al,<sup>8</sup> that 2-phase treatment may result in a poorer final occlusion. The presence of an asymmetric molar relationship at the start of treatment and the non-extraction treatment approach taken, made it more difficult to correct the midline discrepancy observed post-treatment. The use of cross elastics could have corrected this, but this would have further prolonged the treatment and the patient at this stage was satisfied with her occlusion and requested to be debonded.

With respect to cephalometric changes observed at the end of treatment, in both patients, the 2-phase treatment carried out in Patient 2 resulted in a marked reduction in the ANB angle from 90 to 4.50 as against Patient 1, in whom the ANB remained the same (60) at the end of treatment. This reduction in ANB angle occurred mainly due to an increase in the SNB angle by 1.50 in both phases of the treatment, in addition to a slight reduction in the SNA of 20 observed at the end of the first phase of treatment. In addition, the post-treatment ANB angle of Patient 2, compares favorably to that reported by O'Brien et al,<sup>8</sup> in their study of 4.00 and Tulloch et al,<sup>1</sup> of 3.790. In both studies,<sup>1, 8</sup> ANB changes were observed in both 1-phase and 2-phase patients, however, the older age of commencement of treatment of patient 2 (15years) when compared to the lower mean age of the sample population in these studies, may have been responsible for the absence of change in ANB angle observed in Patient 1, in this study. With respect to the upper incisor angulation to the Frankfort plane, in patient 1 a reduction of 160 was observed (from 1230 to 1070) and in Patient 2, a 210 reduction was observed (from 1270 to 1060) at the end of reduction. The greater reduction in upper incisor angulation observed in Patient 2 may be ascribed to the 2-phase treatment used.

One of the limitations of the 2-phase treatment carried out in Patient 2 was that treatment success in the first phase of treatment was entirely dependent on patient's compliance with wearing the Twin block appliance. Poor patient compliance with appliance wear could have unduly prolonged the treatment.

However, this may have been prevented by using a fixed functional appliance such as a fixed twin block or a Herbst appliance. Another limitation was the cost of treatment, considering the fact that the patient had to pay full fees for the second phase of treatment in addition to that, which had been paid for the first phase of treatment. This is in contrast to the 1-phase treatment in patient 1, where the patient only

had to pay for comprehensive fixed appliance therapy. However, as previously highlighted, the issues of cost, may be countered by the benefits obtained from the first phase of treatment. The 2-phase treatment prevented the need for a 2-unit extraction in the upper arch and also reduced the risk of incisal trauma. Furthermore, the improved facial profile and dental appearance of the child after Phase-1 treatment had a positive psychological effect and also improved her self-confidence. Indeed in a previous study, it was reported that some patients, were so satisfied with their appearance after Phase 1 treatment with the Twin Block that they opted out of the second phase of treatment.<sup>8</sup>

In terms of treatment duration, although treatment was unduly prolonged in both patients due to poor compliance with treatment appointments, treatment duration for the 2-phase treatment (Patient 2) was about 9months shorter than that for the 1phase treatment (Patient 1). This finding is contrary to that reported by Tulloch et al,<sup>1</sup> who reported shorter treatment durations for 1-phase treatment. However, poor compliance with clinic appointments and long intervals between clinic appointments may have been responsible for this.

It may be argued that had Patient 1 presented earlier, at say between 10 to 12 years, she could have benefitted from an early treatment (2-phase treatment) and may not have had a two-unit extraction. However, delaying the treatment (1-phase) may not have made any difference to the long term treatment outcomes as highlighted in different studies.<sup>1,8</sup> Thus, as a clinician, there is a need to educate the parents/guardians of children with Class II malocclusion presenting for treatment, on the advantages and limitations/disadvantages of each treatment alternative, i.e 1-phase versus 2-phase treatment. This would enable them make an informed decision on the best treatment option to take.

## Conclusion

One phase and two-phase treatment protocols can be successfully used in the management of Angles Class II Division I malocclusion. Each protocol has its advantages and limitations. However, a thorough patient assessment and selection is required for the best treatment outcome in each case.

## Contributors

G.I Isiekwe conceptualized the paper and treated both patients, while M.N Adekoya completed the treatment for the second patient. O.O daCosta

supervised the treatment of both patients and also contributed to the conceptualization of the paper.

## Funding

Self

## Conflict of Interests

Nil

## References

1. Tulloch JFC, Proffit WR, Phillips C. Outcomes in a 2-phase randomized clinical trial of early Class II treatment. *Am J Orthod Dentofacial Orthop* 2004; 125:657-67.
2. daCosta OO, Utomi IL Referral mode and malocclusion among patients attending Lagos University Teaching Hospital, Lagos. *Odontostomatologie Tropicale* 2009, 32:17-23.
3. Justus R. Are there any advantages of early Class II treatment? *Am J Orthod Dentofacial Orthop* 2008; 134: 717-8.
4. Gianelly A.A. One-phase versus two-phase treatment. *Am J Orthod Dentofacial Orthop* 1995; 108:556-9
5. Hamed A, Khan JI, Ijaz A. Soft tissue facial profile analysis in patients with class I and class II skeletal pattern, visiting children's Hospital Lahore, Pakistan. *Pak oral and Dent J* 2008; 28(2):183-8.
6. Isiekwe GI, daCosta OO. Use of Twin Block of Clark in Management of Angle's Class II Division I Malocclusion. *Case Report N Y State Dent J* 2013 79:41-6.
7. Croft RS, Buschang PH, English JD, Richard M. A cephalometric and tomographic evaluation of Herbst treatment in the mixed dentition. *Am J Orthod Dentofacial Orthop* 1999; 116:435-43
8. O'Brien K, Conboy F, Appelbe P, Davies L, Connolly I et al. Early Treatment for Class II Division I malocclusion with the Twin-block appliance: A multicenter, randomized, controlled trial. *Am J Orthod Dentofacial Orthop* 2009; 135:573-9
9. Brin I, Tulloch JFC, Korluk L, Phillips C. External apical root resorption in Class II malocclusion: a retrospective review of 1-versus 2-phase treatment. *Am J Orthod Dentofacial Orthop* 2003; 124:151-6.
10. Segal GR, Schiffman PH, Tuncany OC. Meta-analysis of the treatment factors of external apical root resorption. *Orthod Craniofac Res* 2004; 71-8.