

A Study relating Taurodontism with Hypodontia and Maxillary Lateral Incisor Microdontia

Yemitan TA^a, Ajisafe OA^b, Ogunbanjo BO^a, Adediran VE^a

Abstract

Background: Certain dental anomalies may coexist in the same patient. Early diagnosis of one anomaly can alert the professional to the possible development of other associated anomalies in the same patient or family, making early diagnosis and timely orthodontic intervention possible. It aims to compare prevalence of hypodontia and maxillary lateral incisor microdontia in a group of children with and without Taurodontism.

Methods: A retrospective study conducted at Orthodontic Unit, Lagos State University Teaching Hospital, Lagos, Nigeria. Orthopantomographs and dental casts of 47 subjects with taurodontism of at least one mandibular first or second permanent molar as an isolated trait were selected. A control group matching the case group for sex and for age at which the records were taken was selected from the same records. These study casts were assessed for microdontia of the maxillary permanent lateral incisors and orthopantomographs were assessed for hypodontia of permanent teeth.

Results: The incidence of microdontia of the maxillary permanent lateral incisor was higher ($p=0.002$) in patients with taurodontism (31.9%, $n = 15$) when compared to the control group with 6.4% ($n = 3$). Hypodontia was present in 14 (29.8%) of subjects with taurodontism while 8 (17%) of the subjects had hypodontia in the control group ($p=0.143$).

Conclusions: There was a significant association between mandibular molar taurodontism and microdontia of maxillary lateral incisors, with increased occurrence of hypodontia of permanent teeth in patients with mandibular molar taurodontism.

Keywords: Hypodontia, Microdontia, Orthodontics, Taurodontism.

Authors' Affiliations

^aDepartment of Child Dental Health,
Lagos State University College of Medicine,
Ikeja, Lagos, Nigeria

^bDepartment of Child Dental Health,
Lagos State University Teaching Hospital,
Ikeja, Lagos, Nigeria

Correspondence

Dr Tolulase Yemitan,
Department of Child Dental Health,
Lagos State University College of Medicine,
Ikeja, Lagos, Nigeria.
+2348023056044
tolulaseyemitan@yahoo.com

Introduction

Dental anomalies are caused by both genetic and environmental factors,¹ and researchers have recognized a growing number of genes associated with early tooth morphogenesis.² These anomalies may occur in combination with other anomalies and some of them, such as taurodontism, are even considered markers of underlying genetic diseases.³

Taurodontism is an alteration in the internal morphology of the pulp chamber, with an apical

displacement of the pulpal floor and bifurcation of the roots, resulting in shortened roots and an enlarged pulp chamber.⁴ It affects molars and premolars in both primary and permanent dentitions. It may affect a single tooth or multiple teeth, either unilaterally or bilaterally.⁵

The prevalence of taurodontism varies among different populations between 2.65% in a Croatian population and 48% in a black Senegalese population.⁶⁻¹⁰ A prevalence of 33% was recorded among Nigerians.¹⁰

The aetiology of taurodontism is still unclear. The consensus is that this condition results from a developmental disturbance in the Hertwig's epithelial root sheath.¹¹ Failure or delay of the ectomesenchyme to induce the epithelium of the root sheath, or failure of the response of the epithelium could result in the delay in the morphogenesis of roots of teeth.¹²

Tooth agenesis is defined as the lack of deciduous and/or permanent teeth due to disturbances of odontogenesis. The prevalence of congenitally missing teeth among different population had been reported with a wide range from 0.3% to 17.1%,¹³⁻²³ of which 6.3% was recorded in a Kenyan population¹⁷ and 9.3% was found among Nigerians.²³ It most commonly involves third molars, affecting 10–25% of the general

population.²⁴ A higher significant prevalence of tooth agenesis in females has been suggested.²⁵ It may be classified as hypodontia, oligodontia, or anodontia. Hypodontia is a term used to describe the absence of one to six teeth, whereas the term oligodontia is applied to agenesis of more than six teeth excluding third molars. The absence of all teeth is termed anodontia and is a rare condition associated with syndromes.²⁴ Certain dental anomalies appear often associated in the same patient, more than expected by chance. Tooth agenesis is frequently associated with other dental anomalies, including microdontia.²⁶⁻²⁸ It is likely that taurodontism and hypodontia may be associated as ectodermal origin has been suggested for both.^{29,30} This suggestion is further supported by the fact that taurodontism may be seen in amelogenesis imperfecta, a defect of ectodermal origin,³¹ which has been associated with different dental anomalies including discolored teeth, microdontia, congenitally missing teeth, taurodontism, pulpal calcification, hypercementosis, and crown and root resorption.³²⁻³⁸

The clinical implications are important because the early diagnosis of a given dental anomaly can alert the professional to the possible development of other associated dental anomalies in the same patient or family, permitting early diagnosis and timely orthodontic intervention.

Previous studies had evaluated the prevalence of these dental anomalies among Nigerian samples,^{10,23,39-42} but to the authors' knowledge, none analyzed the associations that may exist among these dental anomalies.

In this study we investigated the prevalence of hypodontia and microdontia of maxillary lateral incisor in a group of children with Taurodontism in comparison to a control group. The hypotheses were that subjects with taurodontism have significantly increased prevalence of microdontia of permanent maxillary lateral incisor and hypodontia.

Material and Methods

Dental records of consecutive patients who attended a specialist dental clinic in Lagos, Nigeria between December 2013 and September 2014 were screened. The dental and medical records of 220 patients were checked to exclude incidences of caries or trauma and any developmental disorders and syndromes that can affect their dental development.

All the patients were Nigerians. Panoramic radiographs with radiographic evidence of root completion of the permanent mandibular first and second molars were included in the study.

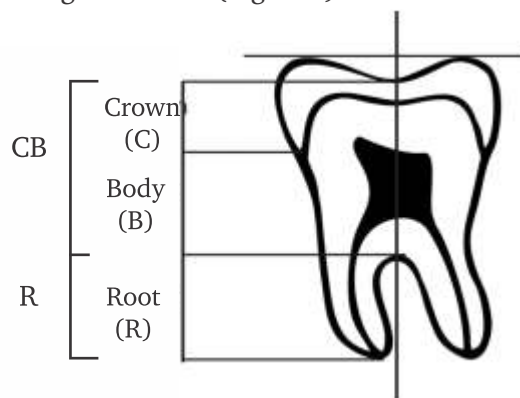
Patients with incomplete records were excluded. Faulty radiographs with unclear or altered tooth morphology of the teeth were excluded. Permanent molars with carious involvement, attrition, or those with restorations or orthodontic appliances were also excluded.

Dental records including panoramic radiographs and dental casts of 127 patients were selected having met the selection criteria. Their mean age at the time of radiography was 18.17 ± 8.9 years (range 10-47 years).

The panoramic radiographs were taken on Planmeca ProMax (Planmeca, USA Inc, IL, USA) at an exposure of 68 KV, 13.0 mA and 15.8 s. All radiographs were viewed in a dark room using an X-ray viewer (Slim-Line™ View Box, Select Dental Manufacturing Inc, NY, USA), and read by two experienced examiners.

This study was carried out with approval from the Research and Ethics committee of the Lagos State University Teaching Hospital.

Taurodontism was assessed using a biometric method used by Seow and Lai⁴³ to measure teeth from the panoramic radiographs. The outlines of first and second mandibular permanent molars teeth were traced from the panoramic radiographs onto acetate tracing paper from which measurements were taken. The parts of each tooth were identified using the following landmarks (Figure 1):



Crown (C) – from the deepest part of occlusal surface to the cemento-enamel junction (CEJ).

Body (B) – from the CEJ to the root furcation.

Root (R) – from the root furcation to the apex.

Figure 1: Anatomical divisions for crown and root lengths of a mandibular permanent molar

The crown and body length (CB) was determined by drawing an occlusal line through the deepest part of occlusal surface which is parallel to another joining the cusp tips. The length CB was determined along a vertical axis drawn at right angle to the occlusal line

measured from the deepest part of occlusal surface to the furcation. Similarly, the root length R was determined along the same vertical axis from the furcation to the root apex. Teeth with a CB:R ratio of < 1.10 were considered normal(Cynodont), those with ratios ≥ 1.10 were considered taurodontic.

The panoramic radiographs were also assessed for hypodontia. A tooth was diagnosed as congenitally missing when it could not be discerned radiographically on the basis of calcification and there was no evidence or history of extraction (Figure 2).

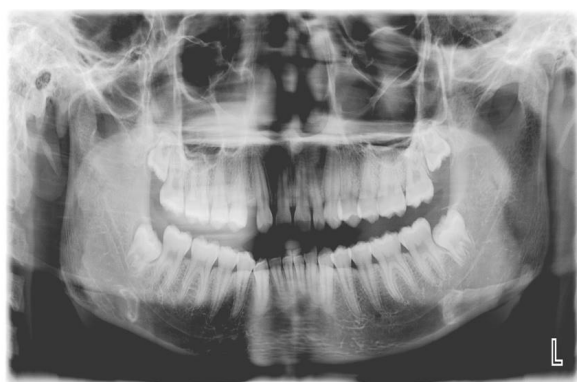

Figure 2: Panoramic radiograph shows hypodontia of maxillary right lateral incisor, microdontia of maxillary left lateral incisor and taurodontism of maxillary and mandibular second molars

The lateral incisors were measured on dental casts using a digital caliper to assess microdontia. A lateral incisor had microdontia when the mesiodistal width was less than the mesiodistal width of the corresponding mandibular lateral incisor.

For every patient with taurodontism from the selected patients' records, a control was randomly selected from the same records who matched the study case for both gender and the age at which the records were obtained.

The reliability of the method was calculated according to Cohen's Kappa, there was 93% inter-observer agreement (P < 0.001).The data was analyzed using Social Package of Statistical Sciences (SPSS) version 21 (Chicago, IL, USA). Pearson's Chi-square tests were used to compare the variables between the groups. The results were considered significant at P < 0.05.

Results

Out of the 220 patients' records examined, 93(42.3%) were excluded for incomplete and faulty records. Of the 127 patients that met the selection criteria, 47 (37%) subjects (20(42.6%) males and

27(57.4%)) females had taurodontism of at least one permanent mandibular molar. Their age range was 10-47years with a mean age of 18.17 ± 8.9 years. The age range of the control group was 10-38years with a mean age of 17.49 ± 9.0 years.

Microdontia of the maxillary lateral incisor was higher in the taurodontism group (Table 1) with 15(31.9%) when compared to the control group with 3(6.4%), this difference was statistically significant (p < 0.05).

Table 1. Prevalence of Microdontia of Maxillary Permanent Lateral Incisor in Patients with Taurodontism Compared to Control

Microdontia of Maxillary Permanent Lateral Incisor	Number of Patients	
	Taurodontism N(%)	Control N(%)
Present	15(31.9)	3(6.4)
Absent	32(68.1)	44(93.6)
Total	47(100.0)	47(100.0)

X² = 9.895, P = 0.0017* * = Significant N = Number

Hypodontia was present in 14(29.8%) of subjects with taurodontism while 8(17%) of the subjects had hypodontia in the control group (Table 2). The difference was not statistically significant (p > 0.05).

Table 2. Prevalence of Hypodontia in Patients with Taurodontism Compared to Control

Hypodontia of Permanent tooth	Number of Patients	
	Taurodontism N(%)	Control N(%)
Present	14(29.8)	8(17.0)
Absent	33(70.2)	39(83.0)
Total	47(100.0)	47(100.0)

X² = 2.136, P = 0.143 N = Number

The pattern of maxillary lateral incisor microdontia associated with taurodontism is shown in Table 3. As observed, 4(26.7%) patients with taurodontism had unilateral microdontia of the maxillary lateral incisor on the right side, 6(40%) had unilateral microdontia of the maxillary lateral incisor on the left side, while 5(33.3%) had bilateral microdontia of the maxillary lateral incisor.

Table 3. Pattern of Maxillary Lateral Incisor Microdontia associated with Taurodontism

Maxillary Lateral Incisor Microdontia	Bilateral N (%)	Unilateral	
		Right N (%)	Left N (%)
Taurodontism Group	5(33.3)	4(26.7)	6(40.0)
Control Group	2(66.7)	0(0)	1(33.3)

$X^2 = 1.169, P = 0.280$

N = Number

Discussion

The present study analyzed the presence and pattern of association between microdontia of the maxillary lateral incisor and taurodontism. It also analyzed any relationship between congenitally missing permanent teeth and taurodontism.

The findings of the present study revealed significant association between microdontia of the maxillary lateral incisor and taurodontism (Table 1). This may indicate a common genetic origin for both dental anomalies causing an aberration of ectodermal derivative. In addition, taurodontism has been reported in many syndromes such as Axenfeld-Rieger syndrome,⁴⁴ incontinentia pigmenti⁴⁵ and Down syndrome⁴⁶ that also feature hypodontia and microdontia. Since these syndromes involve ectodermal defects, it is possible that hypodontia, microdontia and taurodontism are manifestations of an ectodermal defect.

However, it also is possible that a single or concurrent environmental factors may be responsible for the aetiology of these defects. Our findings suggest that if a patient with microdontia of permanent maxillary lateral incisor undergoes orthodontic treatment, careful attention must be given to the possible existence of taurodontism in the mandibular molar region.

Taurodontism was however not significantly associated ($p = 0.280$) with unilateral or bilateral occurrence of microdontia of the maxillary lateral incisor.

The present study found an increased occurrence of hypodontia of one or two congenitally missing teeth in patients with taurodontism which was not statistically significant. This result agrees with some studies that have suggested that association between hypodontia and taurodontism is more likely in cases of severe tooth agenesis, with 6 or more congenitally missing teeth.^{12,47}

Conversely, some studies in the Brazilian population reported no association between tooth agenesis and taurodontism.^{48,49}

Although previous studies have established that the first mandibular molars are minimally distorted on panoramic radiographs and are considered the most stable teeth in the arch and are usually present in hypodontia subjects,⁵⁰ other studies however reported the mandibular second molars the most affected by taurodontism.⁵¹⁻⁵⁵ Thus, both mandibular permanent first and second molars were assessed in the present study.

There are evidently some limitations to the study of congenitally missing teeth as the visibility of tooth germs on radiographs depends on their stage of mineralization. Subjects of same chronologic age may show major differences in mineralization stage and dental age. Tooth buds showing late onset of mineralization could lead to a false positive diagnosis of agenesis on radiographs.⁵⁶ Therefore, diagnosis of tooth agenesis should be made after the age of 6 years, if third molar is excluded and after 10 years of age if the third molar is also studied.⁵⁷ On the basis of this criterion, the age of inclusion in this study was set at 10 years.

The hypothesis that subjects with taurodontism demonstrate increased prevalence of other dental anomalies was corroborated. There was a significant association between mandibular molar taurodontism and microdontia of maxillary lateral incisors, as well as increased occurrence of hypodontia of permanent teeth in patients with mandibular molar taurodontism. These results indicate that clinicians should be aware of the possibility of associated anomalies in patients with these dental anomalies, as well as the accompanying clinical problems associated with these anomalies so as to facilitate a timely orthodontic intervention.

Further studies are necessary to verify a possible association between taurodontism and multiple congenitally missing teeth in a Nigerian population. This will contribute to a better understanding of the aetiology of associated dental anomalies.

Contributors

Yemitan TA contributed to the concepts, design, definition of intellectual content, literature search, data acquisition, data analysis, statistical analysis, manuscript preparation, manuscript review and was the guarantor. Ajisafe OA contributed to the concepts, design, definition of intellectual content, literature search, data acquisition, manuscript preparation and manuscript review. Ogunbanjo BO contributed to the

concepts, design, data analysis, manuscript editing and Manuscript review. Adediran VE contributed to the concepts, design, statistical analysis, manuscript editing and manuscript review

Funding / Grants

The authors hereby disclose that this research was self-funded.

Conflict of Interests

Nil

References

1. Cakan DG, Ulkur F, Taner T. The genetic basis of dental anomalies and its relation to orthodontics. *Eur J Dent* 2013;7:S143-147.
2. Thesleff I. Genetic basis of tooth development and dental defects. *Acta Odontol Scand* 2000;58:191-194.
3. Ezoddini AF, Sheikhha MH, Ahmadi H. Prevalence of dental developmental anomalies: a radiographic study. *Community Dent Health* 2007;24:140-144.
4. Jorgenson RJ. The conditions manifesting taurodontism. *Am J Med Genet* 1982;11:435-442.
5. Haskova JE, Gill DS, Figueiredo JAP, Tredwin CJ, Naini FB. Taurodontism – a review. *Dent Update* 2009;36:235-243.
6. Shifman A, Chananel I. Prevalence of taurodontism found in radiographic dental examination of 1,200 young adult Israeli patients. *Community Dent Oral Epidemiol* 1978;6:200-203.
7. Ruprecht A, Batniji S, el-Neweihi E. The incidence of taurodontism in dental patients. *Oral Surg Oral Med Oral Pathol* 1987;63:743-747.
8. MacDonald-Jankowski DS, Li TT. Taurodontism in a young adult Chinese population. *Dentomaxillofac Radiol* 1993;22:140-144.
9. Toure B, Kane AW, Sarr M, Wone MM, Fall F. Prevalence of Taurodontism at the level of the molar in the black Senegalese population 15-19 years of age. *Odontostomatol Trop* 2000;23:36-39.
10. Yemitan TA, Adediran VE. Prevalence of Taurodontism in Mandibular Molars among Patients at a Dental Care Institution in Nigeria. *Int J Oral Dent Health* 2015;1:020.
11. Jaspers MT, Witkop Jr CJ. Taurodontism, an isolated trait associated with syndromes and X-chromosomal aneuploidy. *Am J Hum Genet* 1980;32:396-413.
12. Shalk-van der Weide Y, Steen WH, Bosman F. Taurodontism and length of teeth in patients with oligodontia. *J Oral Rehabil* 1993;20:401-412.
13. Rosenzweig KA, Garbarski D. Numerical aberrations in the permanent teeth of grade school children in Jerusalem. *Am J Phys Anthropol* 1965;23:277-283.
14. Davis PJ. Hypodontia and hyperdontia of permanent teeth in Hong Kong school children. *Community Dent Oral Epidemiol* 1987;15:218-220.
15. Nik-Hussein NN. Hypodontia in the permanent dentition: a study of its prevalence in Malaysian children. *Aust Orthod J* 1989;11:93-95.
16. Aasheim B, Ögaard B. Hypodontia in 9-year-old Norwegians related to need of orthodontic treatment. *Scand J Dent Res* 1993;101:257-260.
17. Ng'ang'a RN, Ng'ang'a PM. Hypodontia of permanent teeth in a Kenyan population. *East Afr Med J* 2001;78:200-203.
18. Osuji OO, Hardie J. Dental anomalies in a population of Saudi Arabian children in Tabuk. *Saudi Dent J* 2002;14:11-14.
19. Silva Meza R. Radiographic assessment of congenitally missing teeth in orthodontic patients. *Int J Paediatr Dent* 2003;13:112-116.
20. Goya HA, Tanaka S, Maeda T, Akimoto Y. An orthopantomographic study of hypodontia in permanent teeth of Japanese paediatric patients. *J Oral Sci* 2008;50:143-150.
21. Gupta SK, Saxena P, Jain S, Jain D. Prevalence and distribution of selected developmental dental anomalies in an Indian population. *J Oral Sci* 2011;53:231-238.
22. Trakiniene G, Rylis̄kyte M, Kiaušaite A. Prevalence of teeth number anomalies in orthodontic patients. *Stomatologija* 2013;15:47-53.
23. Yemitan TA, Adediran VE, Ajisafe OA, Ogunbanjo BO (2016) A Radiographic study of Non-syndromic Congenitally Missing Teeth in Permanent Dentition of Nigerian Dental Patients. *Int J Dentistry Oral Sci*. 2016;3:258-263.
24. Vastardis H. The genetics of human tooth agenesis: new discoveries for understanding dental anomalies. *Am J Orthod Dentofacial Orthop* 2000;117:650-656.
25. Polder BJ, Van't Hof MA, Van der Linden FP, Kuijpers Jagtman AM. A meta-analysis of the prevalence of dental agenesis of permanent teeth. *Community Dent Oral Epidemiol* 2004;31:217-226.
26. Garn SM, Lewis AB. The gradient and the pattern of crown size reduction in simple hypodontia. *Angle Orthod* 1970;40:51-58.
27. Baccetti T. A controlled study of associated dental anomalies. *Angle Orthod* 1998;68:267-274.
28. Garib DG, Peck S, Gomes SC. Increased occurrence of dental anomalies in patients with second premolar agenesis. *Angle Orthod* 2009;79:436-441.
29. Barjian H: The effect of early dental treatment of anhidrotic ectodermal dysplasia. *J Am Dent Assoc* 1960 ;61:555-569.
30. Jorgenson RJ. The conditions manifesting taurodontism. *Am J Med Genet* 1982;11:435-442.
31. Witkop CJ, Sauk JJ. In *Dental and oral manifestations of hereditary disease*. New York: American Academy of Oral Pathology, 1971.
32. Aldred MJ, Crawford PJ. Variable expression in amelogenesis imperfecta with taurodontism. *J Oral Pathol* 1988;17:327-333.
33. Collins MA, Mauriello SM, Tyndall DA, Wright JT. Dental

- anomalies associated with amelogenesis imperfecta: A radiographic assessment. *Oral Surg Oral Med Oral Pathol Oral Radiol Endod* 1999;88:358–364.
34. Aldred MJ, Savarirayan R, Lamandé SR, Crawford PJ. Clinical and radiographic features of a family with autosomal dominant amelogenesis imperfecta with taurodontism. *Oral Dis* 2002;8:62–68.
 35. Ayers KM, Drummond BK, Harding WJ, Salis SG, Liston PN. Amelogenesis imperfecta – multidisciplinary management from eruption to adulthood. Review and case report. *NZ Dent J* 2004;100:101–104.
 36. Korbmacher HM, Lemke R, Kahl-Nieke B. Progressive pre-eruptive crown resorption in autosomal recessive generalized hypoplastic amelogenesis imperfecta. *Oral Surg Oral Med Oral Pathol Oral Radiol Endod.* 2007;104:540–544.
 37. McDonald S, Arkutu N, Malik K, Gadhia K, McKaig S. Managing the paediatric patient with amelogenesis imperfecta. *Br Dent J* 2012;212:425–428.
 38. Suchancova B, Holly D, Janska M, Stebel J, Lysy J, Thurzo A, et al. Amelogenesis imperfecta and the treatment plan-interdisciplinary team approach. *Bratisl Lek Listy.* 2014;115:44–48.
 39. Onyeaso CO, Onyeaso AO. Occlusal/dental anomalies found in a random sample of Nigerian school children. *Oral Health Prev Dent* 2006;4:181-186.
 40. Oredugba F. Oral health condition and treatment needs of a group of Nigerian individuals with Down syndrome. *Down Syndrome Res Pract* 2007;12:72-76.
 41. Ajayi EO. Prevalence of malocclusion among school children in Benin City, Nigeria. *J Med Biomed Res* 2008;7:1-8.
 42. Temilola DO, Folayan MO, Fatusi O, Chukwumah NM, Onyejaka N, et al. The prevalence, pattern and clinical presentation of developmental dental hard-tissue anomalies in children with primary and mix dentition from Ile-Ife, Nigeria. *BMC Oral Health* 2014;14:125.
 43. Seow WK, Lai PY. Association of taurodontism with hypodontia: A controlled study. *Pediatr Dent.* 1989;11:214–219.
 44. Childers NK, Wright JT. Dental and craniofacial anomalies of Axenfeld-Rieger syndrome. *J Oral Pathol* 1986;15:534–539.
 45. Minic S, Trpinac D, Gabriel H, Gencik M, Obradovi M. Dental and oral anomalies in incontinentia pigmenti: a systematic review. *Clin Oral Investig* 2013;17:1-8
 46. Sekerci AE, Cantekin K, Aydinbelge M, Ucar F. Prevalence of dental anomalies in the permanent dentition of children with Down syndrome. *J Dent Child* 2014;81:78-83
 47. Lai PY, Seow WK. A controlled study of the association of various dental anomalies with hypodontia of permanent teeth. *Pediatr Dent* 1989;11:291-296.
 48. Kuchler EC, Risso PA, Costa Mde C, Modesto A, Vieira AR. Studies of dental anomalies in a large group of school children. *Arch Oral Biol* 2008;53:941-946.
 49. Calvano Kuchler E, De Andrade Risso P, De Castro Costa M, Modesto A, Vieira AR. Assessing the proposed association between tooth agenesis and taurodontism in 975 paediatric subjects. *Int J Paediatr Dent* 2008;18:231-234.
 50. Seow WK. Taurodontism of the permanent mandibular first molar distinguishes between the tricho-dento-osseous (TDO) syndrome and amelogenesis imperfecta. *Clin Genet* 1993;4:240–246.
 51. Blumberg JE, Hylander WL, Goepf RA. Taurodontism: a biometric study. *Am J Phys Anthropol* 1971;34:243-255.
 52. MacDonald-Jankowski. Taurodontism in a young adult Chinese population. *Dentomaxillofac Radiol* 1993;22:140-144.
 53. Bronoosh P, Haghnegahdar A, Dehbozorgi M. Prevalence of taurodontism in premolars and molars in the South of Iran. *J Dent Res Dent Clin Dent Prospects.* 2012;6:21-24
 54. Gupta SK, Saxena P. Prevalence of taurodontism and its association with various oral conditions in an Indian population. *Oral Health Prev Dent.* 2013;11:155-160.
 55. Shah D, Garcha V, Garde J, Ekhande D. Prevalence of taurodontism among the patients visiting a dental teaching Hospital in Pune, India: A retrospective orthopantomogram study. *J Indian Assoc Public Health Dent* 2015;13:83-86.
 56. Polder BJ, Van't Hof MA, Van der Linden FP, Kuijpers-Jagtman AM. A meta-analysis of the prevalence of dental agenesis of permanent teeth. *Community Dent Oral Epidemiol* 2004;32:217-226.
 57. Goya HA, Tanaka S, Maeda T, Akimoto Y. An orthopantomographic study of hypodontia in permanent teeth of Japanese paediatric patients. *J Oral Sci.* 2008;50:143-150.