

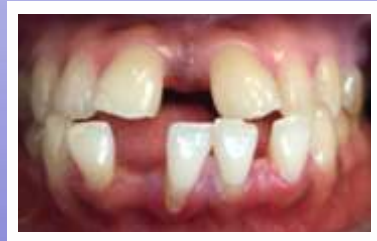# WEST AFRICAN JOURNAL OF ORTHODONTICS

VOLUME 14, NUMBER 2

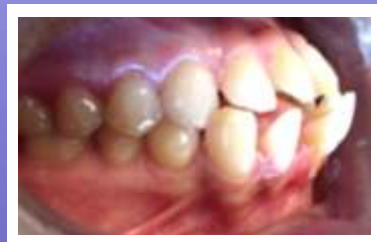ISSN 2315-9502

December 2025

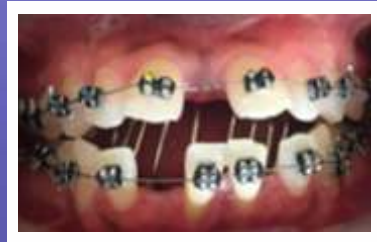
**Cephalometric analysis using a  
mobile application**



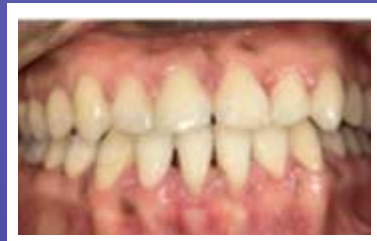**Complications associated with  
orthodontic treatment**



**Case Report: Management of  
Class III malocclusion**



**Abstracts presented at NAO 2025  
Annual Scientific Conference**



## Editor-in-Chief and Editorial Office

Prof. I.G Isiekwe (Nigeria)  
Department of Child Dental Health,  
Faculty of Dental Sciences,  
College of Medicine, University of Lagos,  
Lagos, Nigeria.

## Deputy Editors in-Chief

Dr. T. A Yemitan  
Department of Child Dental Health  
Faculty of Dentistry, Lagos State University  
College of Medicine, Ikeja, Lagos,  
Nigeria.

Dr T. E Adeyemi  
Department of Child Dental Health  
Faculty of Dentistry, College of Health Sciences,  
Bayero University Kano, Kano,  
Nigeria.

## Associate Editors

Prof O.D Otuyemi (Nigeria) (Past Editor in Chief)  
Prof. P.I Ngom (Senegal)  
Prof. M. Newman-Nartey (Ghana)  
Dr. G.K Amoah (Ghana)  
Prof. O.O daCosta (Nigeria)  
Dr. A. Traore-Shumbusho (Nigeria)  
Prof. O.O Sanu (Nigeria)  
Dr. M.A Ernest (Nigeria)  
Dr. O. D Umeh (Nigeria)  
Dr. O. A Aghimien (Nigeria)

## Advisory Editorial Board

Prof. A. Harris (South Africa)  
Dr. H.K Chuan (Malaysia)  
Dr. D. Mahony (Australia)  
Dr. H. Bellardie (UK)  
Dr. J. Noar (UK)  
Prof. P. Hlongwa (South Africa)  
Prof. M.C Isiekwe (Nigeria)  
Dr. A. Soyombo (Nigeria)  
Dr. R. Chamda (South Africa)  
Dr. D. Fashemo (USA)

Website: [www.nao-ng.com](http://www.nao-ng.com)

## Contents

**Editorial** 3

*Isiekwe IG*

### Original Articles

---

**Cephalometric Analysis: Reliability of A Mobile-Based Digital Application: A Pilot Study** 4

*Etim SS, Orikpete MO, Orikpete EV*

**A Three-Year Review of Complications associated with Orthodontic Treatment in A Nigerian Teaching Hospital** 13

*Fadeju AD, Shobayo NM*

**Orthodontic Treatment of A 35year Old With Class III Malocclusion and A Digit Sucking Habit: A Case Report** 21

*Chukwuma EI, Etim SS, Onyeaso CO*

**Abstract Presentation at NAO 2025 Annual Scientific Conference held in Benin** 33

**Pictures from the Conference** 47

**Instructions for Authors** 49

---

# Editorial

Our inaugural Editor in Chief, Professor O.D Otuyemi, who founded the journal in 2012 has taken a bow after leading the Editorial board meritoriously for the past 13 years. The Editorial Board is very grateful to Prof Otuyemi, for his visionary leadership of WAJO, which remains the only orthodontic specialty journal in Sub Saharan Africa and one of the few in the African continent. This edition of the journal marks my first as the new Editor in Chief, and I am very grateful for the opportunity to serve in this capacity.

In this edition, we have an interesting article by Etim et al, which looks at the use of One-Ceph, a smartphone-based mobile application in cephalometric analysis. This is becoming more relevant as artificial intelligence plays a greater role in orthodontic diagnosis and treatment planning. The findings from this pilot study present huge possibilities for the use of these applications in our environment. The study by Fadeju and Shobayo, provides a retrospective review of the complications of orthodontic treatment seen at a tertiary health facility in South-Western Nigeria. The findings of this study provide a better understanding of some of the common complications of orthodontic treatment seen in our environment. The case report by Chukwuma et al provides a detailed description of the orthodontic management of an adult patient with Class III malocclusion and a tongue habit, using the preadjusted edgewise appliance system.

Finally, this edition includes the book of abstracts for the 19<sup>th</sup> Annual Scientific conference of the Nigerian Association of Orthodontists, held in Benin-City, Edo State, from September 23-26, 2025. This provides a detailed summary of each of the 21 oral, poster and case presentations made at the conference. Overall, this is a very interesting and educative edition of the journal which makes for good scientific reading.

**Ikenna Gerald Isiekwe**

*Editor in Chief*

# Cephalometric Analysis: Reliability of A Mobile-Based Digital Application: A Pilot Study

Etim SS<sup>a</sup>, Orikpete MO<sup>b</sup>, Orikpete EV<sup>c</sup>

## Abstract

**Background:** Cephalometric analysis is integral to orthodontic diagnosis and treatment planning. Although conventional manual tracing is accurate, it is time-consuming and prone to operator variability. Digital methods improve precision, yet their adoption in resource-limited settings is restricted by cost and hardware requirements. Smartphone-based applications such as OneCeph® offer a potential low-cost alternative, but independent validation of their accuracy and reliability remains limited. This study compared the reliability of cephalometric measurements obtained using OneCeph® and conventional manual analysis.

**Methods:** A cross-sectional comparative study was conducted using 40 high-quality lateral cephalometric radiographs. Ten standard parameters (six angular: Sella-Nasion-A point (SNA), Sella-nasion-B point (SNB), A point-Nasion-B point (ANB), Upper incisor to nasion-A point (UI-NA), Lower incisor to nasion-B point (LI-NB), Interincisal angle, and four linear: UI-NA, LI-NB, Upper lip to S-line, Lower lip to S-line) were measured manually on acetate film and digitally using OneCeph® (version beta 1.1, NXS Soft Solutions, India). Data were analyzed using intraclass correlation coefficients (ICC), Pearson correlation, and paired t-tests, with significance set at  $p < 0.05$ .

**Results:** Participants' mean age was  $20.7 \pm 7.8$  years; 60% were female. Digital tracings demonstrated good to excellent reliability for skeletal angular and soft tissue parameters (ICC = 0.83–0.91), while manual tracings were slightly more consistent for linear dental measurements (ICC = 0.94 for UI-NA and 0.83 for LI-NB). Statistically significant correlations ( $r \geq 0.90$ ,  $p < 0.001$ ) were observed between both methods for 9 of 10 parameters. However, paired t-test showed a statistically significant mean difference for SNA, SNB, UI-NA°, LI-NB (mm), UL-to-S-line, and LL-to-S-line.

**Conclusion:** Our findings highlight the potential of OneCeph® smartphone-based digital cephalometric analysis in resource-limited settings. However, the statistically significant differences in some parameters observed between digital and manual methods suggest that results obtained using such applications should be interpreted with caution.

**Keywords:** Cephalometric analysis; manual tracing; OneCeph; digital tracing; smartphone application.

## Authors' affiliations

<sup>a</sup>Department of Orthodontics and Paediatric Dentistry,  
Faculty of Dentistry, University of Port Harcourt Port Harcourt, Nigeria  
ORCID: <https://orcid.org/0000-0001-6893-2857>

<sup>b</sup>Department of Child Dental Health, University of Port Harcourt  
Teaching Hospital Port Harcourt, Nigeria  
ORCID: <https://orcid.org/0009-0007-6994-4252>

<sup>c</sup>Department of Oral Pathology, Oral Medicine and Oral Radiology  
Faculty of Dentistry, University of Port Harcourt  
Port Harcourt, Nigeria  
ORCID: <https://orcid.org/0000-0003-4827-7511>

## Correspondence

Efetobo Victor Orikpete  
Department of Oral Pathology, Oral Medicine and Oral Radiology  
Faculty of Dentistry, College of Health Sciences  
University of Port Harcourt, Port Harcourt, Rivers State, Nigeria.  
[efezi2000@yahoo.com](mailto:efezi2000@yahoo.com)  
+2348052100034

## Introduction

Cephalometric analysis was first introduced in 1931 by Broadbent in the United States and Hofrath in Germany, and has since become an essential tool that is used in orthodontics for diagnosis, treatment planning, and monitoring. 1-3 Over time, the lateral cephalometric radiograph has become a gold standard in orthodontics, because it can give reproducible information about the teeth, as well as skeletal and soft tissue relationships. 4-6 Traditionally, the manual method of cephalometric analysis is done by tracing the relevant anatomical landmarks onto acetate film. Thereafter, the various linear and angular relationships are measured using a ruler and protractor. 1,2,7 This process is, however, time-consuming. Also, the accuracy depends on the skill of the operator, especially in being able to identify the landmarks correctly and consistently

every time with minimal variation. Similarly, the same measurement performed by two different operators may give different results due to inter-examiner variability, especially in landmark identification, tracing, and measurement. 8-10

Due to the advancement of digital technology, cephalometric analysis can now be done digitally, either directly on a digital radiograph or by using scanned analogue films. This process typically requires specialized software such as Dolphin Imaging® and WebCeph®. 2,9,11,12 Digital cephalometric analysis significantly improves time efficiency and reproducibility because once the landmarks are identified, all the measurements are obtained automatically. 13-15 Recently, artificial intelligence (AI)-based algorithms have been developed and trained even to identify anatomical landmarks automatically. 16,17 This helps to improve accuracy and reliability. 18,19 In addition, digital cephalometric analysis helps with electronic storage of data, preventing the deterioration of images that can occur over time. 13-15

Despite the many benefits of digital cephalometric analysis, acquiring the required software is often expensive, especially in resource-constrained settings, and there is a need for the necessary computer hardware, which may be bulky. 13,14 To address this problem, smartphone-based applications are now being developed. Such applications enable clinicians to perform cephalometric analysis without needing any special equipment. 6,7

Preliminary studies show that these smartphone-based applications show good reliability and accuracy when compared with conventional manual methods or digital web-based systems. 11,16,19 However, variable results have been obtained for some of the measured linear and angular parameters. Furthermore, how each of these mobile applications performs in clinical settings may be influenced by the particular landmark detection algorithm, as well as the display resolution of the mobile phone being used. As a result, there is a need to independently validate these smartphone-based applications before they can be recommended for clinical use. This study, therefore, aimed to evaluate the reliability of cephalometric measurements obtained with the OneCeph® smartphone

application, compared to conventional manual tracing.

## Materials and Methods

### *Study Design and Setting*

This was an analytical cross-sectional study conducted at the orthodontic unit of the Department of Child Dental Health, University of Port Harcourt Teaching Hospital. Ethical approval was obtained from the Institution's Health Research and Ethics Committee [Protocol number: UPTH/ADM/90/S.11/VOL.XI/1896]. Following an age-appropriate explanation of the study design and objectives, informed consent was obtained from prospective participants. For children, assent was obtained in addition to informed parental consent.

### *Sample Size Determination*

The minimum sample size for this study was estimated based on the formula proposed by Walter, Eliasziw, and Donner (1998) for reliability studies using the intraclass correlation coefficient (ICC) as the primary outcome measure. 20 Assuming two raters (manual and digital tracing methods), an expected ICC of 0.85 (good reliability), a minimum acceptable ICC of 0.60, a significance level ( $\alpha$ ) of 0.05, and 80% statistical power ( $\beta = 0.20$ ), the required sample size was calculated to be approximately 35 paired radiographs. To improve precision, a total of 40 radiographs were included in this study.

### *Sample Selection*

A total of 40 lateral cephalometric radiographs were selected using convenience sampling from prospective orthodontic patients who had cephalometric radiographs taken between January 2024 and December 2024. Inclusion criteria were: high-quality lateral cephalograms with clear visibility of craniofacial landmarks, as well as the central incisors and first molars, and no history of previous orthodontic or orthognathic treatment. Poor-quality radiographs, those with significant artifacts, or incomplete anatomical structures were excluded.

*Manual Cephalometric Tracing*

Each selected cephalogram was printed on acetate film and traced manually using acetate paper, a 0.5 mm pencil, and a protractor, by one of the authors (MOO), a Dental Surgeon with training and clinical experience in cephalometric analysis. Before the cephalometric tracings, the examiner was calibrated using randomly selected cephalograms to ensure standardization of landmark identification and measurement procedures. A standardized light box was used for uniform backlighting. The operator was blinded to the digital results at the time of tracing.

*Digital Cephalometric Tracing*

Each selected cephalogram was printed on acetate film, and high-resolution photographs (300 dpi, 24-bit depth) of the printed cephalograms were obtained using a Samsung Galaxy A14 5G smartphone (Samsung Electronics Co., Ltd., Seoul, South Korea). The smartphone camera was positioned perpendicular to the radiograph at a fixed distance under standardized lighting conditions and without using the zoom feature. The images were subsequently imported into the OneCeph application. Before tracing was performed, each image was calibrated within the OneCeph application using the

embedded scale reference. Manual and digital tracings were performed by the same investigator (MOO) to minimize variability in the measurements. The digital software used was OneCeph® (version beta 1.1; NXS Soft Solutions, Hyderabad, India), a freely available Android application designed for digital cephalometric analysis. Anatomical landmarks were identified using the software's point-and-click tool, and all measurements were computed automatically by the software. To minimize bias, digital analyses were done after completion of all manual tracings, and the investigator was blinded to the manual measurements during digital analysis.

*Landmarks and Measurements*

Measurements of ten cephalometric parameters were done using both manual and digital methods. (Table 1) These included:

Angular: SNA, SNB, ANB, UI to NA (°), LI to NB (°), interincisal angle

Linear: UI to NA (mm), LI to NB (mm), UL to S-line, LL to S-line

All landmarks were identified according to standard cephalometric protocols.<sup>5</sup> Measurements obtained using both manual and digital tracings were then compared.

**Table 1. The cephalometric landmarks and measurements utilized in this study. <sup>21</sup>**

Category	Parameter	Definition
Points	S (Sella)	The midpoint of the cavity of the Sella turcica
	Na (Nasion)	The anterior point of the intersection between the nasal and frontal bones
	Point A:	The innermost point on the contour of the premaxilla between the anterior nasal spine and the incisor tooth
	Point B:	The innermost point on the contour of the mandible between the incisor tooth and the bony chin
Angular	SNA (°)	Angle between the Sella–Nasion line and Nasion–Point A line
	SNB (°)	Angle between the Sella–Nasion line and Nasion–Point B line
	ANB (°)	The difference between SNA and SNB
	UI to NA (°)	The angle between the long axis of the upper incisor and the NA line
	LI to NB (°)	The angle between the long axis of the lower incisor and the NB line
	Interincisal angle (°)	The angle between the long axes of the upper and lower incisors
Linear	UI to NA (mm)	The perpendicular distance from the upper incisor tip to the NA line
	LI to NB (mm)	The perpendicular distance from the lower incisor tip to the NB line
	UL to S-line (mm)	The distance from the upper lip to Steiner's S-line
	LL to S-line (mm)	The distance from the lower lip to Steiner's S-line

### *Reliability Assessment*

Cephalometric analysis using both manual and digital methods was performed over a 14-day period to minimize examiner fatigue, with an average of 3 radiographs analyzed each day. To assess intra-examiner reliability, 10 radiographs were randomly selected and re-traced using both methods after a 2-week interval. Intra-examiner reliability was assessed using the intraclass correlation coefficient (ICC), applying a two-way mixed-effects model with absolute agreement definition. Grading of ICC was done using the model proposed by Koo and Li 22.

### *Statistical Analysis*

Data were entered into a spreadsheet and analyzed using IBM SPSS Statistics version 25.0 (IBM Corp., Armonk, NY, USA). Descriptive statistics (means, standard deviations) were computed for each parameter. Paired sample t-tests were used to compare the mean differences between manual and digital measurements. Pearson's correlation coefficients were calculated to assess the strength of association between the two methods. A  $p$ -value  $\leq 0.05$  was considered statistically significant.

## **Results**

### *Sample Characteristics*

A total of 40 lateral cephalograms were analyzed in this study. The mean age of the participants was  $20.7 \pm 7.8$  years, with a range from 9 to 42 years. Out of the 40 participants, 24 (60.0%) were females and 16 (40.0%) were males.

### *Reliability assessments*

Reliability estimates for manual and digital tracings are summarized in Table 2. Digital tracings demonstrated good to excellent reliability for skeletal angular parameters such as SNA, SNB and ANB (ICC = 0.83–0.91). Manual tracings showed a similar range (0.71–0.91) but displayed slightly lower consistency for the ANB and SNB angles. In contrast, certain linear dental parameters such as UI–NA (mm) and LI–NB (mm) yielded higher reliability with manual tracings (ICC = 0.94 and 0.83, respectively) compared with the corresponding digital values (ICC = 0.74 and 0.72). For angular dental measurements

(UI–NA° and LI–NB°), both techniques showed good reliability, while the interincisal angle displayed excellent agreement (ICC = 0.91) across both methods. Soft tissue parameters (upper and lower lip to the S-line) also demonstrated excellent consistency for both manual and digital tracings (ICC  $\geq 0.92$ ).

Although most ICC values suggested good reproducibility, several parameters exhibited wide confidence intervals, particularly for ANB and SNB angles, indicating variability likely related to sample size and operator factors. Overall, both methods yielded comparable levels of measurement reliability, with the manual method showing marginally greater precision for certain linear dimensions.

### *Correlation Between Manual and Digital Measurements*

Descriptive statistics were computed for each of the 10 paired cephalometric parameters assessed manually and digitally. Pearson correlation coefficients showed strong, statistically significant positive correlations ( $p < 0.001$ ) between values obtained from manual tracings compared with those obtained from digital tracing for 9 out of the 10 parameters studied (Table 3). The only exception was UI to NA linear, which showed a weaker correlation ( $r = 0.244, p = 0.129$ ).

### *Comparison of Manual and Digital Cephalometric Measurements*

Digital values for SNA, SNB, and UI to NA angle were higher than manual values. A similar trend was observed for both soft tissue parameters (UL to S-Line and LL to S-Line). Statistically significant ( $p < 0.05$ ) differences of the paired samples t-tests were found in six of the ten measured parameters: SNA, SNB, UI to NA angle, LI to NB linear, UL to S-Line, and LL to S-Line. On the other hand, no significant differences were observed between manual and digital values for: ANB, UI to NA linear, LI to NB angle, and Interincisal angle (Table 4).

**Table 2. Reliability assessment using the intraclass correlation coefficient (ICC) for both manual and digital cephalometric tracings**

Parameter	Manual ICC (95% CI)	Digital ICC (95% CI)
SNA angle, °	0.83 (0.48-0.95)	0.86 (0.57-0.96)
SNB angle, °	0.78 (0.20-0.94)	0.88 (0.20-0.97)
ANB angle, °	0.71 (0.11-0.93)	0.83 (0.41-0.96)
UI – NA, mm	0.94 (0.78-0.98)	0.74 (0.28-0.93)
UI – NA angle, °	0.91 (0.65-0.98)	0.86 (0.55-0.96)
LI – NB, mm	0.83 (0.45-0.96)	0.72 (0.06-0.93)
LI – NB angle, °	0.89 (0.63-0.98)	0.87 (0.59-0.97)
Interincisal angle, °	0.91 (0.65-0.99)	0.91 (0.87-0.99)
Upper lip to S-line, mm	0.95 (0.82-0.99)	0.92 (0.59-0.98)
Lower lip to S-line, mm	0.95 (0.82-0.99)	0.93 (0.82-0.99)

ICC < 0.50: Poor reliability; 0.50 – 0.75: Moderate reliability; 0.75 – 0.90: Good reliability; > 0.90: Excellent reliability

**Table 3. Correlation between manual and digital cephalometric measurements**

Paired sample (Manual vs Digital)	Correlation coefficient <sup>a</sup>	p-value
SNA	0.913	< 0.001
SNB	0.959	< 0.001
ANB	0.916	< 0.001
UI to NA (Linear)	0.244	0.129
UI to NA (Angular)	0.605	< 0.001
LI to NB (Linear)	0.984	< 0.001
LI to NB (Angular)	0.945	< 0.001
Interincisal Angle	0.953	< 0.001
UL to S-Line	0.916	< 0.001
LL to S-Line	0.946	< 0.001

<sup>a</sup> Pearson correlation coefficient ( $r > 0 \leq 0.19$ , very weak;  $r \geq 0.2 \leq 0.39$ , weak;  $r \geq 0.4 \leq 0.59$ , moderate;  $r \geq 0.6 \leq 0.79$ , strong;  $r \geq 0.8$  very strong)

**Table 4. Paired sample t-test comparison between cephalometric values obtained via manual and digital tracing**

Parameter	Manual tracing			Digital (One Ceph) tracing			Mean difference	p-value
	Mean	SD	SE	Mean	SD	SE		
SNA angle, °	88.51	5.61	0.89	89.66	5.32	0.84	-1.1450	0.003
SNB angle, °	86.36	5.41	0.86	87.29	4.83	0.76	-.9250	0.001
ANB angle, °	2.19	3.67	0.58	2.24	3.36	0.53	-.0525	0.822
UI – NA, mm	11.82	6.45	1.02	16.92	18.90	2.99	-5.1000	0.088
UI – NA angle, °	26.81	11.57	1.83	31.70	9.63	1.52	-4.8825	0.003
LI – NB, mm	14.42	6.61	1.04	14.95	6.81	1.08	-.5250	0.009
LI – NB angle, °	33.94	8.58	1.36	34.73	8.81	1.39	-.790	0.093
Interincisal angle, °	112.62	8.51	1.34	112.49	8.26	1.31	0.1300	0.751
Upper lip to S-line, mm	10.44	7.65	1.21	11.86	7.36	1.16	-1.4200	0.006
Lower lip to S-line, mm	12.08	7.67	1.21	13.64	7.48	1.18	-1.5650	0.000

SD = Standard deviation, SE = Standard Error of mean

## Discussion

In this study, we evaluated the reliability of cephalometric measurements obtained using a mobile-based digital application when compared with those gotten by conventional manual tracing. The level of agreement between methods was assessed using paired sample t-tests, while reproducibility of the digital measurements was assessed using intra-class correlation coefficients (ICCs). Our results show that both digital and manual methods were reliable when used for repeated measurements. Furthermore, the mobile-based digital application gave results that were not significantly different from those obtained by manual tracing in 40% of the measured parameters.

The digital tracing method was reliable for all the assessed parameters, with the reliability ranging from moderate to excellent. This shows that the mobile-application produced consistent measurements when used by the same examiner under standardized

conditions. In a previous systematic review, Narkhede et al, reported that digital methods were sufficiently reliable for most cephalometric parameters. 18 Similarly, other authors have shown excellent reliability for both web-based 11 and mobile-based 8 digital cephalometric analysis tools. The digital method was slightly less reliable for some linear measurements of incisal position (UI–NA mm, LI–NB mm), which is similar to the findings of Hassan et al 8, and this may be due to the sensitivity of this landmark to changes in placement position, as well as poor radiographic clarity that may occur in jaws when visualizing structures around the midline. 4,23 AI-based platforms that incorporate automated landmark detection may help reduce this potential source of error, thereby improving reliability. 18 Other authors 9,11,13 have also shown that digital cephalometric analysis gives more reliable and consistent results for angular measurements than for linear ones. Both methods gave excellent

reproducibility for soft tissue parameters.

Our results also show strong positive correlations between manual and digital methods for nine of the ten evaluated parameters ( $r \geq 0.9$ ), with the exception being the UI-NA (linear), which showed a weak correlation ( $r = 0.244$ ,  $p = 0.129$ ). However, paired t-test analyses showed that, for some of the skeletal and dental parameters assessed (ANB, LI – NB angular, UI – NA, linear, and interincisal angle), there were no statistically significant differences between the mean values obtained from manual and digital tracing. This suggests that, for these parameters, the two methods yield comparable mean measurements. On the other hand, statistically significant differences were observed in six out of ten (SNA, SNB, UI to NA, angular, LI to NB (linear), UL to S-Line, and LL to S-Line) cephalometric parameters when comparing the mean values obtained using manual and digital methods. This indicates that the agreement between manual and digital techniques may vary depending on the specific cephalometric parameter being evaluated. Our findings contrast with those of Kunz et al, who did not find any difference between cephalometric analysis done by humans and that done using artificial intelligence algorithms. 24 The differences observed may be because, in the current study, landmark identification was done manually. AI-based algorithms for automated landmark identification may be less error-prone, as their accuracy has been shown to approach 98%. 25

Some angular measurements (SNA and SNB), as well as the soft tissue measurements (UL to S-Line and LL to S-Line), showed higher values in results obtained using digital analysis. A similar pattern was seen in some previous studies 6,7, and may be the result of subtle variations in landmark identification, method of manual tracing, or placement of the protractor during measurements. 23 Since digital cephalometric images can be enhanced (e.g., by adjusting the brightness/contrast or by being able to zoom in and out), this may improve the ability to

visualise subtle anatomical landmarks. 18 This increased precision may explain the slightly higher angular measurements for SNA and SNB when using digital tools. The significant differences observed in the upper and lower lip to S-line measurements suggest that soft-tissue landmarks may be less consistently identified when using digital tools, probably because of their lower contrast on radiographs. 4

In this study, only one examiner performed all the cephalometric tracings and analyses. Although this was deliberate, to avoid inter-examiner variability, this may limit the generalizability of our findings. Further studies with a larger sample size may be useful in validating the findings to this study or adding to the body of evidence.

### Conclusion

Although our findings highlight the potential of smartphone-based digital cephalometric analysis in resource-limited settings, we cannot conclude about the ability of the mobile-based digital application assessed in this study to serve as a substitute for the manual method. Instead, the findings of this study show that while the digital application gives reproducible results, agreement with manual tracing may vary depending on the specific parameter being measured. Thus, the results obtained with such applications should be interpreted with caution.

### Conflict of interest

The authors declare that they have no conflict of interest

### Funding

No funding was received for this study

### Authors' contributions

SSE conceptualized the study, MOO did all the cephalometric tracings, EVO did the data analysis, MOO and EVO wrote the initial draft of the manuscript. All authors reviewed the final draft of the manuscript.

## References

1. Shrestha R, Kandel S. A comparative study on use of manual versus digital method using mobile application for cephalometric measurements. *Orthod J Nepal*. 2020;10(1):11–6. doi:10.3126/ojn.v10i1.27714
2. Collins J, Shah A, McCarthy C, Sandler J. Comparison of measurements from photographed lateral cephalograms and scanned cephalograms. *Am J Orthod Dentofacial Orthop*. 2007;132(6):830–3. doi:10.1016/j.ajodo.2006.05.024
3. Broadbent BH. A new X-ray technique and its application to orthodontia. *Angle Orthod*. 1931;1(2):45–66. doi:10.1043/0003-3219(1931)001<0045:ANXTAI>2.0.CO;2
4. Jeon S, Lee KC. Comparison of cephalometric measurements between conventional and automatic cephalometric analysis using convolutional neural network. *Prog Orthod*. 2021;22(1):34. doi:10.1186/s40510-021-00374-8
5. Jacobson A. *Radiographic cephalometry: From basics to 3-D imaging*. 2nd ed. Hanover Park (IL): Quintessence Publishing; 2006.
6. Mohan A, Sivakumar A, Nalabothu P. Evaluation of accuracy and reliability of OneCeph digital cephalometric analysis in comparison with manual cephalometric analysis—a cross-sectional study. *BDJ Open*. 2021;7(1):15. doi:10.1038/s41405-021-00070-6
7. Zamrik OM, Iseri H. The reliability and reproducibility of an Android cephalometric smartphone application in comparison with the conventional method. *Angle Orthod*. 2021;91(2):236–42. doi:10.2319/032320-245.1
8. Hassan MM, Alfaifi WH, Qaysi AM, Alfaifi AA, AlGhaffli ZM, Mattoo KA. Comparative evaluation of digital cephalometric tracing applications on mobile devices and manual tracing. *Med Sci Monit*. 2024;30:e943929. doi:10.12659/MSM.943929
9. Celik E, Polat-Ozsoy O, Toygar Memikoglu TU. Comparison of cephalometric measurements with digital versus conventional cephalometric analysis. *Eur J Orthod*. 2009;31(3):241–6. doi:10.1093/ejo/cjn099
10. Silva TP, Hughes MM, dos Santos Menezes L, de Melo MFB, de Freitas PHL, Takeshita WM. Artificial intelligence-based cephalometric landmark annotation and measurements according to Arnett's analysis: can we trust a bot to do that? *Dentomaxillofac Radiol*. 2022;51(6):20220045. doi:10.1259/dmfr.20220045
11. Prince STT, Srinivasan D, Duraisamy S, Kannan R, Rajaram K. Reproducibility of linear and angular cephalometric measurements obtained by an artificial-intelligence assisted software (WebCeph) in comparison with digital software (AutoCEPH) and manual tracing method. *Dental Press J Orthod*. 2023;28(1):e232922. doi:10.1590/2177-6709.28.1.e232922
12. Çoban G, Öztürk T, Hashimli N, Yağci A. Comparison between cephalometric measurements using digital manual and web-based artificial intelligence cephalometric tracing software. *Dental Press J Orthod*. 2022;27(4):e222064. doi:10.1590/2177-6709.27.4.e222064
13. Goracci C, Ferrari M. Reproducibility of measurements in tablet-assisted, PC-aided, and manual cephalometric analysis. *Angle Orthod*. 2014;84(3):437–42. doi:10.2319/070213-492.1
14. Tsorovas G, Linder-Aronson K. A comparison of hand-tracing and cephalometric analysis computer programs with and without advanced features—accuracy and time demands. *Eur J Orthod*. 2010;32(6):721–8. doi:10.1093/ejo/cjp164
15. Erkan M, Gurel HG, Nur M, Demirel B. Reliability of four different computerized cephalometric analysis programs. *Eur J Orthod*. 2012;34(3):318–21. doi:10.1093/ejo/cjr005
16. Arik SO, Ibragimov B, Xing L. Fully automated quantitative cephalometry using convolutional neural networks. *J Med Imaging*. 2017;4(1):014501.
17. Lee H, Park M, Kim J. Cephalometric landmark detection in dental X-ray images using

- convolutional neural networks. *Proc SPIE Med Imaging Comput Aided Diagn.* 2017;10134:494–9.
18. Narkhede S, Rao P, Sawant V, Sachdev SS, Arora S, Pawar AM, Reda R, Testarelli L. Digital versus manual tracing in cephalometric analysis: a systematic review and meta-analysis. *J Pers Med.* 2024;14(6):566. doi:10.3390/jpm14060566
  19. Barbhuiya MH, Kumar P, Thakral R, Krishnapriya R, Bawa M. Reliability of mobile application based cephalometric analysis for chair side evaluation of orthodontic patient in clinical practice. *J Orthod Sci.* 2021;10:16. doi:10.4103/jos.JOS\_89\_20
  20. Walter SD, Eliasziw M, Donner A. Sample size and optimal designs for reliability studies. *Stat Med.* 1998;17(1):101–10. doi:10.1002/(SICI)1097-0258(19980115)17:1<101::AID-SIM727>3.0.CO;2-E
  21. Proffit WR, Fields HW Jr, Sarver DM. Orthodontic diagnosis: the problem-oriented approach. In: *Contemporary orthodontics*. 6th ed. Philadelphia (PA): Elsevier; 2019. p. 184–192.
  22. Koo TK, Li MY. A guideline of selecting and reporting intraclass correlation coefficients for reliability research. *J Chiropr Med.* 2016;15(2):155–63. doi:10.1016/j.jcm.2016.02.012
  23. Baumrind S, Frantz RC. The reliability of head film measurements: landmark identification. *Am J Orthod.* 1971;60(2):111–27. doi:10.1016/0002-9416(71)90028-5
  24. Kunz F, Stellzig-Eisenhauer A, Zeman F, Boldt J. Artificial intelligence in orthodontics: evaluation of a fully automated cephalometric analysis using a customized convolutional neural network. *J Orofac Orthop.* 2020;81(1):52–68.
  25. Araidy S, Batshon G, Mirochnik R. Artificial intelligence applications in dentistry: a systematic review. *Oral.* 2025;5(4):90.

# A Three-Year Review of Complications associated with Orthodontic Treatment in A Nigerian Teaching Hospital

Fadeju AD<sup>a</sup>, Shobayo NM<sup>b</sup>

## Abstract

**Background:** Orthodontic interventions, though effective in correcting malocclusions, can lead to undesirable oral complications that may affect treatment efficiency and patient comfort. Therefore, this study aimed to document complications occurring during and shortly after orthodontic management and the treatment duration with fixed or removable appliances at the Obafemi Awolowo University Teaching Hospitals Complex (OAUTHC), Ile-Ife, between 2021 and 2023, in order to examine relationship between these complications and treatment length.

**Methods:** This was a retrospective analysis that involved the review of clinical records of patients who received orthodontic care within the study period. Information on complication categories, duration of treatment, and appliance type was extracted. Statistical analyses were conducted using SPSS (version 25), and associations between variables were tested with the Chi-square method. Approval for the study was granted by the Institutional Ethics Committee (IPH/OAU/12/2034).

**Results:** Out of 90 eligible patient records, the most common adverse event was gingival hyperplasia (63.1%), followed by gingival pain and swelling (17.9%), mucosal ulceration (9.5%), and other less frequent periodontal issues (9.5%). A statistically significant difference was observed between complication type and treatment stage ( $\chi^2 = 19.13$ ,  $df = 7$ ,  $p = 0.008$ ). A statistically significant difference was also seen between complication type and treatment duration ( $\chi^2 = 52.41$ ,  $df = 21$ ,  $p < 0.001$ ).

**Conclusion:** Orthodontic complications varied between stages of treatment and duration. Gingival hyperplasia emerged as the predominant complication, particularly in prolonged treatment cases. Routine periodontal assessment and timely intervention may reduce the incidence and severity of such outcomes.

<sup>a</sup>Dr. **Fadeju**, Adeyemi Dada. B.Ch.D. FWACS,  
Department of Child Dental Health, Faculty of Dentistry,  
Obafemi Awolowo University, Ile-Ife, Osun State & Department  
of Child Dental Health, Obafemi Awolowo University Teaching  
Hospitals Complex, Ile-Ife, Osun State, Nigeria.

E-mails: [afadeju@oauife.edu.ng](mailto:afadeju@oauife.edu.ng);

[dadafadeju@yahoo.com](mailto:dadafadeju@yahoo.com)

<sup>b</sup>Dr. **Shobayo**, Nawaal Morenike B.Ch.D

Faculty of Dentistry, College of Health Sciences, Obafemi  
Awolowo University, Ile-Ife, Osun State, Nigeria.

E-mail: [faiqahbntaaj@gmail.com](mailto:faiqahbntaaj@gmail.com)

## Corresponding Author:

Dr Fadeju, Adeyemi Dada,  
Department of Child Dental Health,  
Faculty of Dentistry, Obafemi Awolowo University, Ile-Ife,  
Osun State, Nigeria.

Tel: 08034019343

E-Mail: [afadeju@oauife.edu.ng](mailto:afadeju@oauife.edu.ng); [dadafadeju@yahoo.com](mailto:dadafadeju@yahoo.com)

## Introduction

Orthodontics, derived from the Greek words *ortho* (which means straight or correct) and *odont* (which means tooth), is a specialized branch of dentistry that addresses the diagnosis, prevention, interception, correction of orofacial irregularities and malocclusion<sup>1</sup>

Malocclusion has negative effects on craniofacial development, oral health and function, and patients' psychological and social life. If left untreated it increased the risk of individual to be prone to oral complications like periodontal disease, caries and gingival inflammation, as well as systemic diseases resulting from impaired mastication and altered nutrition.<sup>2,3</sup>

Orthodontic treatment plays a crucial role in correcting malocclusion and enhancing dental function and facial appearance. Despite improvements in treatment techniques and appliance designs, orthodontic care still presents with challenges. Patients may experience complications at various stages of treatment, ranging from mild discomfort to more serious dental or periodontal problems such as caries, mucosal injuries, gingival inflammation, and other tissue damages that may affect patient comfort, treatment progress, and outcomes.<sup>4,5</sup> Patient's oral hygiene, type of orthodontic appliance, period of treatment, and individual susceptibility are important factors influencing the occurrence of these complications<sup>5</sup>.

The different types of appliances used for orthodontic treatments are associated with different types of oral health problem. The fixed orthodontics appliances, are linked with plaque retention and gingival changes, while removable appliances may cause injuries to the soft tissue.<sup>6</sup> Identifying the types and frequency of such complications is important, as it allows clinicians to expect possible side effect, tailor possible preventive strategies, and provide appropriate patients awareness, this in turn enables orthodontics to counsel patients on prevention and improve treatment.

This aim of this study was to identify and compare the types and frequency of complications experienced by patients associated with the use of fixed and removable appliances during orthodontic treatment over a period of three years (2021–2023) at the Orthodontic Unit of the Obafemi Awolowo University Teaching Hospital Complex (OAUTHC), Ile-Ife.

### **Materials And Methods**

This study employed a retrospective cross-sectional design employing the use of existing patient records from the Orthodontic Unit of the Obafemi Awolowo University Teaching Hospitals Complex (OAUTHC) in Ile-Ife, Nigeria.

All patients that had received or were receiving orthodontic treatment over a three-year period from 2021 to 2023, with either fixed or removable appliances were included in the study. Patients who had orthognathic surgery and patients with incomplete documentation or who stopped treatment before the first review visit were excluded.

Sociodemographic data recorded, include age categorized into 6–15, 16–25, 26–35, and above 35years, sex (male or female), and occupation (student, unemployed, artisan, civil servant, or self-employed). Clinical and treatment-related variables were also documented, such as the type of orthodontic appliance used (fixed, removable, or sectional fixed), the stage of treatment at the time data collection (ongoing or completed), where ongoing treatment referred to cases with appliances still in place and completed treatment referred to cases in which appliances had been removed before data

extraction, and treatment duration, classified into one-year increments ranging from one to eight years.

Complications associated with treatment were identified from the patient records and recorded as present or absent. Complications were recorded only when clearly documented in the patients' clinical records by attending orthodontist.

- Dental caries: Records indicating visible decay on occlusal or aproximal tooth surfaces were classified as dental caries.
- Generalized gingival hyperplasia: Defined as gum enlargement that extended more than one quadrant of the mouth.
- Mucosal ulceration: Described as soreness or breakdown of the oral lining in contact with appliance
- Gingival pain and swelling: Referred to patient reported gingival discomfort accompanied by clinically documented gingival swelling in the absence of abscess formation.
- Periodontal pocket with gingival swelling: Defined as a periodontal pocket recorded in association with gingival swelling at the same site.
- Gingival abscess: Identified from description of painful, localized swellings with pus discharge
- Chronic generalized gingivitis: Defined as generalized gingival inflammation affecting the multiple sites, characterized by erythema, swelling, or bleeding

Entries reporting localized gum pain with observable swelling were recorded accordingly as stated in the patients clinical records.

For certain analyses, complications were grouped into four categories: generalized gingival hyperplasia; mucosal ulceration; gingival pain and swelling; and other complications, which encompassed dental caries, periodontal pocket with swelling, gingival abscess with swelling, and chronic generalized gingivitis. Only patient with complete documentation of complications and treatment stage were included in the analysis.

### **Data Analysis**

Data analysis was performed using statistical software, Statistical Package for the Social Sciences (SPSS) version 25. Descriptive statistics were

calculated to summarize all categorical variables, with frequencies and percentages. Inferential analysis was conducted using the Chi-square Test of Independence. Two primary associations were tested: between the original eight complication types and the stage of treatment, and between the four complication categories and treatment duration. Statistical significance was set at  $p \leq 0.05$

**Ethical consideration**

Ethical approval for the study was obtained from the OAUTHC Institutional Review Board. (IPH/OAU/12/2034). The study was conducted using anonymized patient records. A waiver was obtained for participants' informed consent.

**Results**

A total of 90 patient records were reviewed for this study. Most of the patients fell into the 16–25-year age group (44.4%), with a smaller number in the 25–26 years range (25.6%) and the 7–15 years range. Only (9.3%) of the patients were between 36 and 50 years old. There were more female patients than the males. The patients were predominantly Students (64.4%), while civil servants accounted for about one-fifth. Others were self-employed (8.9%), artisans (3.3%), and unemployed (2.2%). Fixed appliances therapy was the most common treatment type (94.4%), with only 2.2% patients treated with removable or sectional fixed appliances (1.1%). At the time of review, most cases (70.6%) were still ongoing treatment (Table 1)

**Table 1: Sociodemographic and types of orthodontic treatment**

Age Category	Frequency (n=90)	Percentage (%)
7-15	19	21.1
16-25	40	44.4
26-35	23	25.6
36-50	8	9.3
<b>SEX</b>		
Male	30	33.3
Female	60	66.7
<b>OCCUPATION</b>		
Student	58	64.4
Unemployed	2	2.2
Artisan	3	3.3
Civil servant	19	21.1
Self employed	8	8.9
<b>TYPE OF APPLIANCE</b>		
Fixed appliance	87	94.4
Removable appliance	2	2.2
Sectional fixed appliance	1	1.1
<b>STAGES OF TREATMENT</b>		
ONGOING	64	70.6
COMPLETED	26	29.5

A higher percentage of the patients (58.9%) did not have complications. Among those who had complications, the most frequent was gingival pain and swelling (16.7%), followed by gingival hyperplasia (8.9%) and periodontal pockets with

swelling (6.7%), mucosal ulceration (3.3%) and Occlusal caries (2.2%) chronic generalized gingivitis (2.2%) and gingival abscess with pain (1.1%) were less common (Table 2)

**Table 2: Treatment complications of participants**

Treatment Complication Frequency	Frequency (n)	Percentage (%)
Dental caries	2	2.2
Generalized gingival hyperplasia	8	8.9
Mucosal ulceration	3	3.3
Periodontal pocket and gingival swelling	6	6.7
Gingival pain and swelling	15	16.7
Gingival abscess and pain	1	1.1
Chronic generalized gingivitis	2	2.2
No complication	53	58.9

Chi-square analysis showed a statistically significant association between the type of complication and the treatment stage ( $\chi^2 = 19.13$ ,  $df = 7$ ,  $p = 0.008$ ). Most patients without complications were still undergoing

treatment, whereas certain complications, such as gingival pain and swelling, appeared more frequently in completed cases. (Table 3)

**Table 3: Cross tabulation of complications vs stage of treatment**

Treatment Complication	Ongoing n (%)	Completed n (%)	Total n (%)
Occlusion caries	1 (50.0)	1 (50.0)	2 (100.0)
Generalized gingival hyperplasia	6 (75.0)	2 (25.0)	8 (100.0)
Mucosal ulceration	2 (66.7)	1 (33.3)	3 (100.0)
Periodontal pocket and gingival swelling	3 (50.0)	3 (50.0)	6 (100.0)
Gingival pain and swelling	6 (40.0)	9 (60.0)	15 (100.0)
Gingival abscess and pain	1 (100.0)	0 (0.0)	1 (100.0)
Chronic generalized gingivitis	0 (0.0)	2 (100.0)	2 (100.0)
No complication	45 (84.9)	8 (15.1)	53 (100.0)
<b>Total</b>	<b>64 (71.1)</b>	<b>26 (28.9)</b>	<b>90 (100.0)</b>

**Chi-square test:**  $\chi^2 = 19.129$ ,  $df = 7$ ,  $p = 0.008$ .

Note: 75% of the cells had an expected count below 5.

Complications were classified as generalized gingival hyperplasia (Category 1), Category 2 – mucosal ulceration, Category 3 – gingival pain and

swelling, and Category 4 – other complications (Dental caries, periodontal pocket with swelling, gingival abscess with swelling, chronic generalized

gingivitis). Types of complications differed significantly across treatment durations ( $\chi^2 = 52.41$ ,  $df = 21$ ,  $P = 0.001$ ). The most frequent category was category 1 (63.1%), which occurred mainly in the patients treated for 2 to 4 years. While Category 2

(9.5%) occurred predominantly within the first year (50%), Category 3 (17.9%) peaked at three years (40%), and Category 4 (9.5%) was concentrated in the patients treated for three years (50%) and eight years (25%) (Table 4)

**Table 4: Complication versus Treatment duration (N=84)**

Complication category	1yr	2yrs	3yrs	4yrs	5yrs	6yrs	7yrs	8yrs	Total (%)
Gingival hyperplasia	1(1.9)	20(37.7)	12(22.6)	12(22.6)	3(5.7)	1(1.9)	2(3.8)	2(3.8)	53(63.1)
Mucosal ulceration	4(50.0)	1(12.5)	2(25.0)	0(0.0)	0(0.0)	1(12.5)	0(0.0)	0(0.0)	8(9.5)
Gingival pain/swelling	2(13.3)	1(6.7)	6(40.0)	1(6.7)	2(13.3)	3(20.0)	0(0.0)	0(0.0)	15(17.9)
Other complications	0(0.0)	1(12.5)	4(50.0)	0(0.0)	1(12.5)	0(0.0)	0(0.0)	2(25.0)	8(9.5)
Total	7(8.3)	23(27.4)	24(28.6)	13(15.5)	6(7.1)	5(6.0)	2(2.4)	4(4.8)	84(100)

**Discussion**

This retrospective review of 90 orthodontic patient records from the Orthodontic Unit of the Obafemi Awolowo University Teaching Hospitals Complex, Ile-Ife, covered three years (2021–2023) and aimed to identify complications associated with the use of fixed and removable appliances during treatment and immediately after completion. Most patients were young adults aged 16–25 years, with female students making up the largest group. Fixed appliances were used in almost all cases, and just over two-thirds of treatments were still ongoing at the time of review. Slightly more than half of the patients had no recorded complications. Among those who experienced adverse events, the most common were gingival pain and swelling, followed by generalized gingival hyperplasia. When grouped into categories, gingival hyperplasia accounted for nearly two-thirds of all complications. Statistical analysis showed significant associations between the type of complication and both the stage of treatment and the duration of appliance use.

This study offers several notable strengths. It represents the first documentation of orthodontic complication patterns in a Nigerian tertiary hospital, filling an important gap in the regional literature. The methodology was standardized, with clearly defined

inclusion and exclusion criteria and systematic data extraction from clinical records. The analysis was comprehensive, combining descriptive summaries with inferential statistics to explore associations between variables. Ethical standards were upheld through institutional approval and the use of anonymised patient data, ensuring confidentiality and compliance with research governance requirements.

The analysis revealed distinct patterns according to treatment stage and duration. During active treatment, gingival hyperplasia, gingival pain and swelling, and periodontal pockets were the most prevalent findings, whereas post-treatment records showed persistent gingival pain and swelling in a substantial proportion of patients. Complication patterns were also time-dependent: mucosal ulceration peaked in the first year, likely reflecting the adaptation phase; gingival pain and swelling were most frequent in the third year, suggesting cumulative inflammatory changes; and gingival hyperplasia was most common between the second and fourth years, consistent with prolonged plaque retention and chronic irritation<sup>22</sup>. Statistical testing confirmed significant associations between complication type and both treatment stage.

These findings align closely with prior evidence from Nigerian<sup>7</sup> and international literature<sup>6,8</sup> showing that

fixed appliances predispose to inflammatory complications due to plaque accumulation around brackets and wires. This heightened susceptibility necessitates rigorous oral hygiene practices and regular professional intervention to mitigate these adverse effects throughout the treatment duration.<sup>9</sup>

The demographic profile of the cohort predominantly young adults, most of whom were students mirrors that reported in other Nigerian orthodontic studies<sup>10,11</sup> and may explain challenges with oral hygiene compliance<sup>7,11</sup> which can heighten the risk of inflammatory complications.<sup>12</sup> Age-related behavioral factors, such as dietary choices and inconsistent brushing routines, appear to play a significant role in the onset and severity of plaque-induced conditions during orthodontic treatment.<sup>13,14</sup> In addition, the age can be associated with varying levels of oral hygiene awareness and compliance.<sup>15</sup> These issues underscore the critical importance of investigating the specific patterns of inflammatory complications and oral hygiene challenges within diverse orthodontic patient populations.<sup>16</sup> This study's analysis of the prevalence and contributing factors of inflammatory complications among orthodontic patients in a Nigerian tertiary healthcare setting provides insights into localized oral health challenges.<sup>17</sup> Such regional data are crucial for developing targeted preventive strategies and tailored patient education programs to improve orthodontic outcomes and minimize iatrogenic effects.<sup>18</sup> In addition, this paper contributes to the broader understanding of orthodontic sequelae by highlighting the specific complications encountered within this demographic, including issues related to gingival recession<sup>19</sup> and the efficacy of various preventive measures<sup>20</sup>

The study observed that mucosal ulceration occurred among patients using removable appliances, although this appliances were used in only a small fraction of cases, this observation is consistent with earlier reports attributing mucosal ulceration during removable orthodontic therapy to trauma from appliance components, especially from clasps during the initial adjustment period,<sup>21,23</sup>. The infrequent use

of removable appliances in the present study limited the depth of analysis possible for their associated complications. Further research exploring the specific design characteristics of removable appliances and the length of their adaptation period would help clarify the mechanisms that contribute to mucosal trauma.

The timing of these complications provides further clinical insight. Early treatment stages were marked by appliance adaptation issues such as ulceration<sup>23</sup> mid-treatment years by sustained inflammatory responses leading to hyperplasia<sup>6,24</sup> and pain<sup>25</sup> and extended treatments by increased risk of caries and periodontal pockets<sup>26,27</sup>. The persistence of gingival pain and swelling after treatment completion suggests delayed resolution of inflammation<sup>25</sup> and underscores the need for post debonding monitoring.

These results carry practical implications. Preventive measures should be tailored to treatment phases: early in treatment, strategies such as protective wax and targeted hygiene instruction may reduce ulceration<sup>28</sup> in the mid-treatment years, intensified prophylaxis, including antimicrobial rinses, can help counteract hyperplasia and discomfort<sup>6</sup> and in longer treatments, periodontal surveillance and caries-preventive measures such as fluoride varnish<sup>26</sup> are warranted. Following appliance removal, scheduled follow-up visits can address residual inflammation<sup>25</sup> and promote tissue healing.

In conclusion, fixed appliances at OAUTHC were strongly associated with time-dependent gingival inflammation, which often peaked mid-treatment and sometimes persisted beyond therapy. Mucosal ulceration was more characteristic of early removable appliance use, though its low occurrence limited detailed evaluation. The adoption of stage-specific preventive protocols focused on hygiene reinforcement and inflammation control could improve treatment outcomes. Future prospective studies that track oral hygiene status and patient compliance will be essential to confirm causal pathways and refine prevention strategies.

### Limitation

This study is limited by its retrospective design, which relied on existing patient records and may have missed undocumented complications. Many of the complication categories had small counts, which limits the strength of the statistical power. Being a single-center study may limit generalizability, and important confounders, including oral hygiene, socioeconomic status, and patient compliance, were not measured. Furthermore, the operational definition of dental caries in this study was restricted to occlusal and interproximal lesions, excluding enamel decalcification and labial surface caries. This restriction may have led to an underestimation of the true burden of caries-related complications and

represents a source of classification bias. Finally, the lack of post-treatment follow-up may have underestimated late-onset complications. These limitations should be considered when interpreting the findings.

### Conflict of interest

The authors declare that they have no conflict of interest

### Funding

No funding was received for this study

### Authors' contributions

FAD conceptualized the study. SNM collected all the data. FAD did the data analysis. FAD and SNM wrote the initial draft of the manuscript. All authors reviewed the final draft of the manuscripts.

### References

1. Karton K. The evolution and impact of orthodontics on modern dentistry. *J Orthop Trauma Relat Res*. 2024; 19(5):96-100.
2. "Orthodontics." *Cleveland Clinic*, 10 Dec. 2022, my.clevelandclinic.org/health/treatments/24285-orthodontics. Accessed 10 Feb. 2024.
3. Guo L, Feng Y, Guo H, Liu B, Zhang Y, Chen H. Consequences of orthodontic treatment in malocclusion patients: clinical and microbial effects in adults and children. *BMC Oral Health*. 2016;16:110.
4. Khursheed, Al-Janabi A, Farooq I, Al-Mutairi F, Vohra F, Naseem M. Complications Arising Due to Orthodontic Treatment-A Systematic Review and Meta-Analysis." *ResearchGate*. 2023. [www.researchgate.net/publication/369417479](http://www.researchgate.net/publication/369417479). Accessed 2 Dec. 2023.
5. Moresca, R. Orthodontic treatment time: can it be shortened? *Dental Press Journal of Orthodontics*, 2018; 23(6), 90–105.
6. Kerosuo H, Kerosuo E, Niemi M, Simola H. The occurrence of adverse effects during orthodontic treatment. *J Orofac Orthop*. 2013;74(6):457-64.
7. Sallam N.H, Ibrahim M.M, Abo El Fadl E.M. Gingival overgrowth during orthodontic treatment: risk factors and management. *Orthod Craniofac Res*. 2020; 23(2):226–34.
8. Umezulike NO, Otuyemi OD, Daramola OO, Kolawole KA. Complications encountered during orthodontic treatment in a Nigerian teaching hospital. *Niger J Clin Pract*. 2020;23(7):985-91.
9. Bollen AM, Cunha-Cruz J, Bakko DW, Huang GJ, Hujuel PP. The effects of orthodontic therapy on periodontal health: a systematic review of controlled evidence. *J Am Dent Assoc*. 2008;139(4):413-22..
10. Scribante A, Sfondrini MF, Collesano V, Tovt G, Bernardinelli L, Gandini P. Dental hygiene and orthodontics: effect of ultrasonic instrumentation on bonding efficacy of different lingual orthodontic brackets. *Biomed Res Int*. 2017; 2017:3714651.
11. Ajayi, E. O., Ladeinde, A. L., & Akinmoladun, V. I. (2018). Pattern of orthodontic treatment in a Nigerian tertiary hospital. *African Journal of Oral Health*, 8(1), 23–29.
12. Otuyemi OD, Oladoyinbo T, Sanu OO. Oral health behaviour, patient/parent-orthodontist relationship, and compliance of Nigerian adolescents to fixed orthodontic appliance treatment. *West Afr J Orthod*. 2017;6(2).
13. Masoe, A., Blinkhorn, A., Taylor, J., & Blinkhorn, F. An assessment of preventive care offered to orthodontic patients by oral health therapists in NSW Australia. *International Dental Journal*, 2015; 65(4), 196.
14. Bui CH, Seldin EB, Dodson TB. Types, frequencies, and risk factors for complications after third molar extraction. *J Oral Maxillofac Surg*. 2003;61(12):1379-89.Scott, P. M., Fleming, P. S., & DiBiase, A. T. An Update in Adult Orthodontics. *Dental Update*, 2007; 34(7), 427.
15. Guo, J., Li, L., Guan, G., Bennani, F., & Mei, L. Oral health knowledge and practice among orthodontic clients in China and New Zealand. 2020; 54(3), 124.

16. Migliorati M, Isaia L, Cassaro A, Rivetti A, Silvestrini-Biavati F, Gastaldo L, Piccardo I, Dalessandri D, Silvestrini-Biavati A. Efficacy of professional hygiene and prophylaxis on preventing plaque increase in orthodontic patients with multibracket appliances: a systematic review. *Eur J Orthod.* 2014;37(3):297-307.
17. Mahjoub, D. T., AlJabri, R. K., Bifari, N. E., & Najjar, R. S. Oral hygiene awareness and practice in orthodontic patients in Makkah city: A cross sectional study. *Journal of Orthodontic Science*, 2023; 12(1).
18. Lupi, J. E., Handelman, C. S., & Sadowsky, C. Prevalence and severity of apical root resorption and alveolar bone loss in orthodontically treated adults. *American Journal of Orthodontics and Dentofacial Orthopedics*, 1996; 109(1), 28.
19. Northway, W. Gingival recession—can orthodontics be a cure? Evidence from a case presentation. *The Angle Orthodontist*, 2013; 83(6), 1093.
20. Sharma R, Mittal AK, Agarwal V. Caries preventive measures among Rajasthani orthodontists: a questionnaire study. *J Evol Med Dent Sci.* 2014;3(32):8811-5.
21. Song YL, Tan ELY, Chua BCJ, Ng RJY, Lam NKP. Interceptive orthodontic treatment in Singapore: a descriptive study. *Proc Singap Healthc.* 2020;29(2):109-14.
22. Guo R, Lin Y, Zheng Y, Li W, Li Y. Clinical and microbial effects of fixed orthodontic appliances on periodontal health. *BMC Oral Health.* 2016;16(1):98.
23. Okunseri C, Hodges JS, Alaki SM, et al. Soft tissue lesions among orthodontic patients: prevalence and risk factors. *Int Dent J.* 2022; 72(5):609–15.
24. Agbelusi GA, Akinboboye BO, Oredugba FA, et al. Comprehensive evaluation of factors that induce gingival overgrowth in orthodontic patients. *Niger J Clin Pract.* 2021;24(11):1563–9.
25. Ristic M, Vlahovic Svabic M, Sasic M, Zelic O. Clinical and microbiological effects of fixed orthodontic appliances on periodontal tissues in adolescents. *Orthod Craniofac Res.* 2007;10(4):187-95
26. Ahn HW, Lee DY, Kim SH, et al. Long-term orthodontic treatment and its effects on periodontal health: a retrospective study. *Korean J Orthod.* 2017; 47(4):222–32.
27. Sundararaj D, Venkateshwaran S, Dinesh SP, et al. Assessment of periodontal status in patients undergoing fixed orthodontic treatment. *J Indian Soc Periodontol.* 2019;23(2):150–5
28. Alshammari F, Alshammari A, AlGhamdi L. Effectiveness of oral hygiene instructions and professional cleaning in reducing orthodontic treatment complications: a systematic review. *J Orthod Sci.* 2022;11(1):12.

# Orthodontic Treatment of A 35year Old With Class III Malocclusion and A Tongue Sucking Habit: A Case Report

Chukwuma EI<sup>a</sup>, Etim SS<sup>b</sup>, Onyeaso CO<sup>b</sup>

## Abstract

**Background:** A case of a 35-year-old female physician who presented to the department of Child Dental Health, University of Port Harcourt Teaching Hospital with complaints that she has never been caught smiling on camera due to the arrangement of her teeth. She was observed to have Angle's class III sub-division left malocclusion on skeletal base pattern III, complicated by crossbite of all anterior teeth, a tongue sucking habit, severe spacing on both arches and a compromise of her lower anterior periodontal tissues. Baseline cephalometric values were SNA 83°, SNB 91°, ANB -8°, UIFP 136° and LIMP 103°.

**Methods:** A comprehensive fixed orthodontic therapy of both arches was done using preadjusted edgewise Roth's 022 slot in addition to a fixed tongue rake on the upper arch. The work up to her management involved the preventive and restorative dentists.

**Results:** At the end of management patient was discharged with class I molar relationship, the anterior crossbites were corrected and all the spaces were effectively closed-up. Cephalometric values at the time of debonding were SNA 85°, SNB 90°, ANB -5°, UIFP 126° and LIMP 85.5°.

**Conclusion:** After 25 months of management, the patient was satisfied with the aesthetic and psychosocial outcomes of management. Retention was done with both fixed and ESSIX retainers on both arches.

**Keywords:** Class III malocclusion, Tongue sucking, Anterior crossbite, Spaced dentition, Interarch-elastics.

## Authors' affiliations

<sup>a</sup> Department of Child Dental Health, University of Port Harcourt Teaching Hospital, Port Harcourt, Rivers State

<sup>b</sup> Department of Orthodontics and Paediatric Dentistry, Faculty of Dental Sciences, University of Port Harcourt, Rivers State

## Correspondence:

**Chukwuma**, Emmanuel Ifeanyi  
Department of Child Dental Health  
University of Port Harcourt Teaching Hospital, Port Harcourt,  
Rivers State  
P.M.B. 6173, Port Harcourt  
Telephone number +2348023046596  
E-mail [iceacema@gmail.com](mailto:iceacema@gmail.com)

## Introduction

Class III malocclusion accounts for the lowest prevalence rates of occlusal abnormalities in African populations with mean values being less than 5%<sup>1,2</sup>. Here in River State, Nigeria prevalence of class III malocclusion (1.6%)<sup>3</sup>, similar to rates obtained in Benin City (1.8%)<sup>4</sup> and in Northern Nigeria (2%)<sup>5</sup>, also accounts for the lowest rate of occlusal abnormalities. Much higher rates (12%) were however recorded among indigenous

populations in the metropolitan city of Lagos State, Nigeria<sup>6</sup>. Among 10-15-year-olds in Calabar metropolis class III recorded a prevalence of 4.1% and still maintained the lowest prevalence among other forms of malocclusion

In the simplest form Class III malocclusion may be defined as a type of malformation characterized by a mesial molar relationship.<sup>1</sup> In more severe cases Class III malocclusion has also been defined with discrepancies of dental or skeletal components in antero-posterior, vertical and sagittal directions<sup>8</sup>. It may be classified as pseudo-Class III malocclusion and skeletal Class III malocclusion<sup>9</sup>. It may also be classified into Dental type, Skeletal type and Functional type of Class III malocclusion.<sup>10</sup>

The type or class of Class III malocclusion presented by a patient, plays a vital role in the complexity and Management options open to a clinician, hence the regular evolution and revision of classification with focus on occlusal relationship and treatment planning<sup>11</sup>. Other integral factors that influence treatment planning include aetiology, chronological age and maturity stage of the patient. The reliable

tools in determining the structural aetiology in class III malocclusion are cephalometric, facial and occlusal analysis.<sup>12</sup>

A practical classification that focuses on aetiology

and occlusal relationship to aid treatment planning classifies it into Dental class III and Skeletal class III, with sub types A, B and C as shown in Table 1 below.

**Table 1: Classification of class III malocclusion<sup>12</sup>**

Types	Skeletal Classification	Dental Classification (Dewey)
A	Short or retrognathic maxilla	Molar in Class III with anterior edge to edge
B	Long or prognathic mandible	relationship Molar in class III with crowded mandibular
C	Combination of Both	incisors Molar in class III with anterior crossbite

In situations where anterior crossbite is present in class III malocclusion case, it is generally assumed to further complicate management and is also assumed to tend towards a skeletal crossbite. It is important at this point to differentiate the crossbite into a dental and skeletal one. Some important criteria that help to achieve this differentiation include dental assessment where occlusal features of the maxillary and mandibular arch are examined, profile assessment for the extent of maxillary and mandibular development and functional assessment for centric relation/centric occlusion discrepancy<sup>12</sup> assessment.

The major management options for class III malocclusions are Growth modification, Class III Camouflage and Orthognathic surgery.<sup>13</sup> When growth modification is no longer and option due age, borderline cases and Moderate cases of skeletal class III can be successfully treated with camouflage<sup>14</sup>. Furthermore, proper selection and adequate application of biomechanics and orthodontic appliances can make very difficult cases and severe skeletal class III look easy<sup>12,13,15,16</sup>. The main objective of orthodontic camouflage involves proclination of the maxillary anteriors and retroclination of the mandibular anteriors by selective extractions, fixed appliance with class III intermaxillary elastics and en masse distalization of mandibular dentition using temporary anchorage devices.<sup>17</sup> The major drawback of very successful orthodontic camouflage is compromised aesthetics due to low maxillary prominence and increased chin prominence due to en mass retraction and retroclination of lower anterior segment. This has given birth to 'Orthognathic camouflage' Orthodontic clockwise rotation of the

maxillomandibular complex for improved facial profile.<sup>18</sup>

This case reports the use of a unique inter-arch elastic placement method 'Class III-Cross-Elastic' in addition to management of a tongue sucking habit in the correction of class III malocclusion in a 35-year-old female physician.

**Case Report**

This is a report that involves a married 35-year-old female family physician that works in University of Port Harcourt Teaching Hospital and resides in the city of Port-Harcourt. Her presenting complain was “I don't like the arrangement of my teeth and you cannot catch me smiling on camera”. There were positive history of Tongue sucking and thrusting Habit and positive history of psychosocial impact due to the malocclusion. There was no confirmed past family history of such malocclusion but presently her children have similar malocclusions.

Extraoral examination revealed a concave facial profile and a class III skeletal pattern. Patient also presented with potentially competent lips with a Jackson score of 3/0 at rest. Intraorally there were high labial frenal attachments and gingival recessions of teeth 31, 41 and 42 with resultant Grade I mobility involving the teeth 31 and 41. All the incisors had minor Ellis Class I trauma apart from teeth 41 and 42. Patient also had dental caries involving teeth 38, 47 and 48.

The lower arch showed an expanded lower arch anteriorly with severe asymmetric spacing of 11mm which was more on the right with resultant deviation of the lower midline to the left by 3mm. There was

distolabial rotation of teeth 41 and 42 in addition to distal and labial tilting involving teeth 31, 41 and 42. The mandibular buccal segment showed only 1mm spacing on the right and left. The maxillary arch also revealed severe spacing of 9mm with a midline diastema of 6mm. There was also distal tilting of all the maxillary incisors and distolabial rotation of the centrals. In occlusion, patient was found to have class III incisor relationship and a negative overjet of 5mm with an anterior crossbite extending from right canine to left canine. The molar relationship was also an Angle's class III subdivision left.

Panoramic radiograph showed that patient has all compliment of teeth apart from the maxillary right second molar. The periapical radiograph of the mandibular anterior segment suggested a bone loss that affected the upper third of the roots of incisor teeth. Lateral cephalometric radiograph suggested that the patient's problem maybe due to a horizontal growth pattern as evidenced by Frankfurt mandibular plane angle of 19° (24-26°) and a Y axis angle of 51° (53-66°). The skeletal base was found to be a class III due to ANB of -8° (2-4°) and supported by Witt's of -11mm (+2mm to -2mm). The mandibular skeletal base appeared to be prognathic with SNB value of 91°

(82.7° ± 3°) while the maxillary skeletal base was orthognathic, with SNA value of 83° (85.5° ± 3.5°). In contrast with the skeletal base assessment, the maxillary incisors were proclined with UI/FP of 136° (119-127°) while the mandibular incisor appeared normal with LI/MP of 103° (96-104°).

A multidisciplinary assessment by the Orthodontists, Periodontist, Endodontist and Conservative dentists made a diagnosis of Angle's class III subdivision left malocclusion on skeletal pattern 3 complicated by reverse overjet of (-) 5mm, crossbite of 11, 12, 13, 21, 22 and 23, severe lower anterior spacing of 11 mm, severe upper anterior spacing of 9 mm with mid line diastema of 6mm, mild lower posterior spacing of 1 mm on the right and left, expanded anterior segment of the lower arch, anterior resting position of the tongue and a tongue sucking habit, rotations of teeth 11, 13, 21, 32, 41 and 42, distal tilting 11, 12, 21, 22, 41 and 42, potentially competent lips of 3/0, non-coincident dental midlines with lower deviated 3mm to the left, lisping speech, dental caries of 38, 47 and 48, Ellis class I trauma involving teeth 11, 12, 21, 22, 31 and 32, gingival recession of 31, 41 and 42, Grade I mobility of 31 and 41

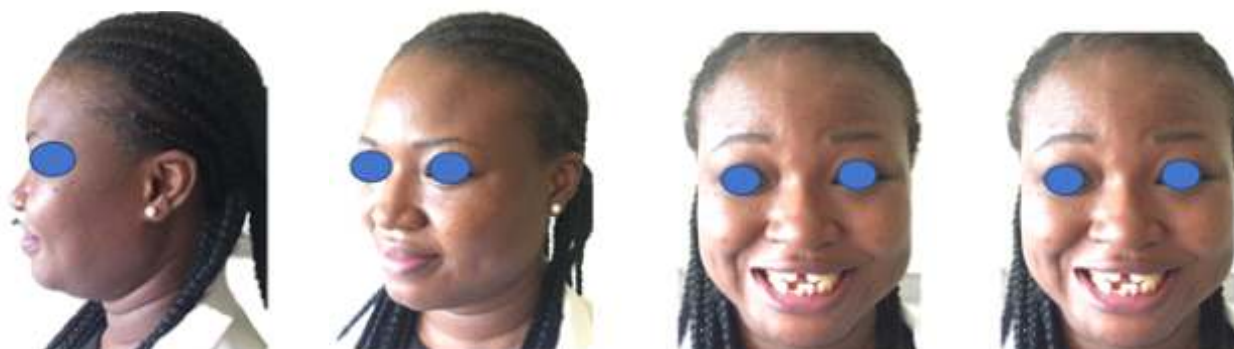

Figure 1: Pretreatment Extraoral photographs

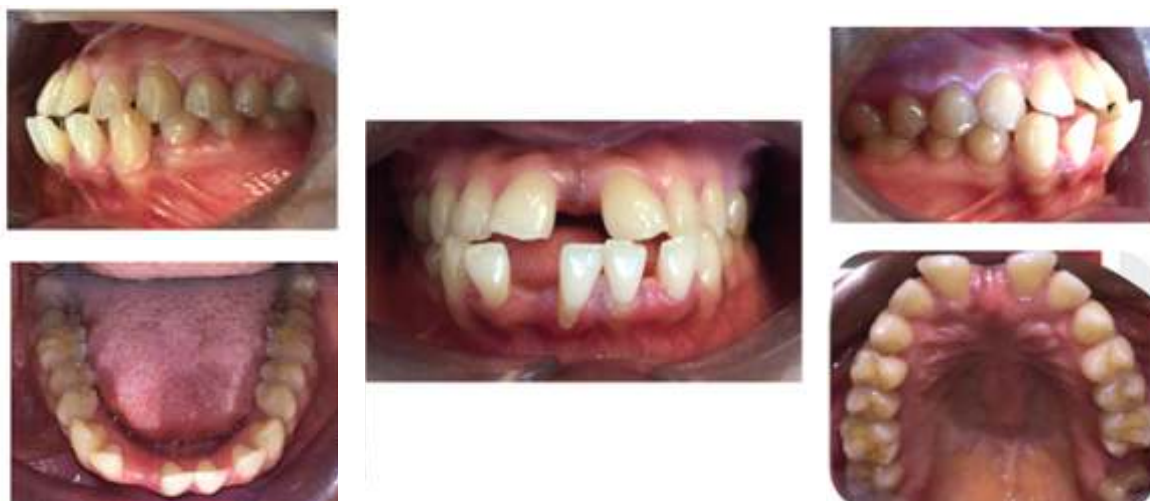

Figure 2: Pretreatment intraoral photographs

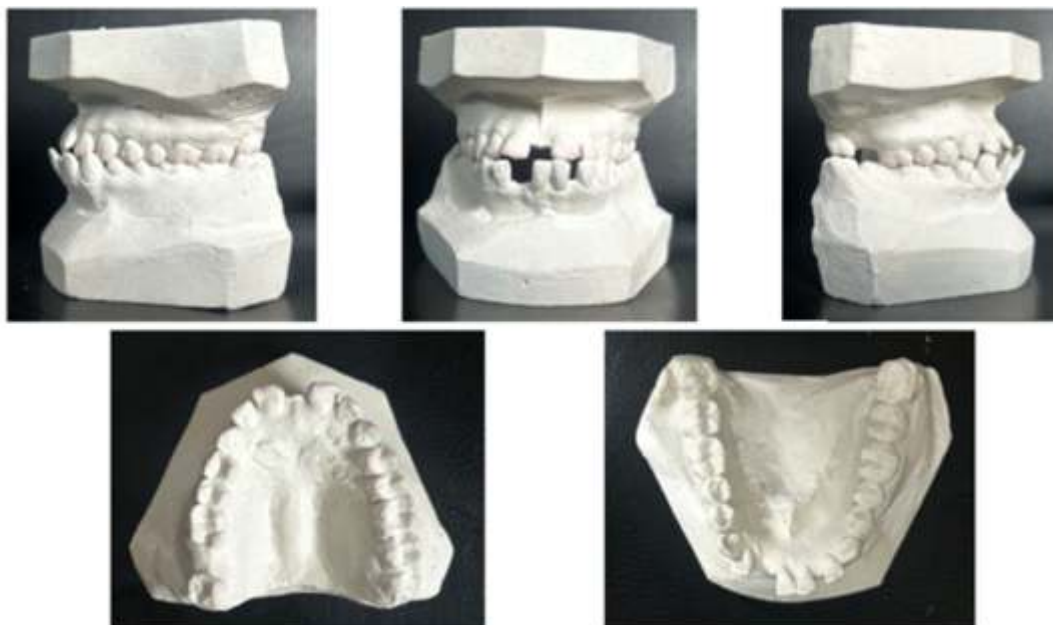

Figure 3: Pretreatment study models

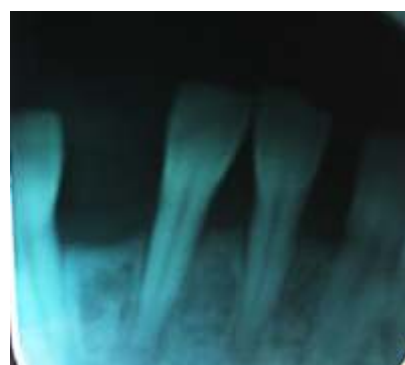
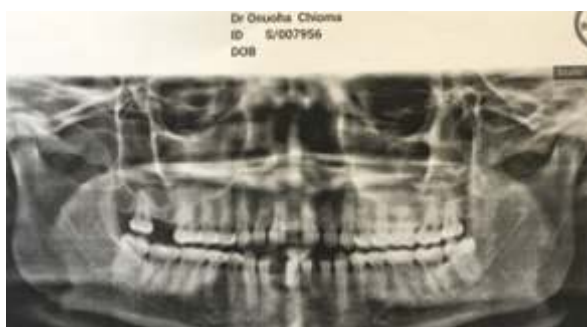
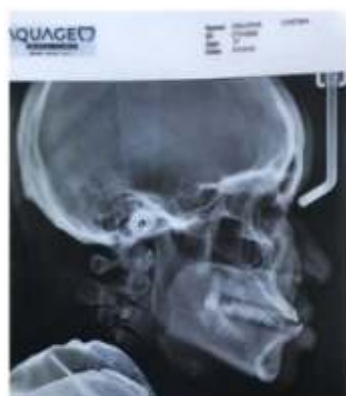Figure 4: Pretreatment dental panoramic and periapical radiographs



Parameter	Pt value
SNA	83°
SNB	91°
ANB	-8°
WITT	-11mm
UI/FP	136°
LI/MP	103°
U1/L1	103°
FMPA	19°
LFH%	59.5% (66/111)
Y AXIS	51°
JARABAK RATIO	68.5% (76/111)

Parameter	Pretreatment values	Ref value
UL- E plane	-2mm	3.21 ± 2.69
LL- E plane	+3mm	6.76 ± 2.83
Nasolabial angle	73°	84.35° ± 13.71°
H angle	17°	7°-15°
Z angle	74°	71°-89°

Figure 5: Pretreatment lateral cephalometric analysis

**Treatment objectives**

The treatment objectives were to: a) to correct and improve on the antero-posterior relationship, b) improve the lower arch width, c) close-up the spaces in the upper and lower arches, d) to correct the rotated tilted teeth, e) to improve on the tongue habit and speech, f) to effectively retain the treatment outcome.

**Management Protocol**

The sequence and protocol adopted to manage this patient was a multidisciplinary approach which involved the following.

1. A comprehensive pre-orthodontic counselling to explain in details all the procedures, treatment options and timings that may be required in addition to all specialties that may be needed to achieve favourable treatment outcomes.
2. Referral to the Periodontist for general prophylaxis and instruction on hygiene. The periodontist would also assess the high labial frenal attachment to plan the timing for intervention and assess periodontal health of periodontally involved teeth for fitness.
3. Referral to the conservative dentist for caries management of involved teeth and to lay down recurrence prevention plan. The conservative dentist was also expected to plan for the management of the multiple fractured teeth.
4. Referral to the endodontist to assess the endodontic health of the mobile mandibular central incisors with loss of periodontal support. This is to rule-out perio-endo-lesion and need for endodontic treatment.
5. Orthodontic management involves the use of full upper and lower fixed orthodontic appliance (standard preadjusted edgewise Roth .022 x .028- in-

slot prescription) with incorporated fixed tongue rake.

6. Effective retention plan involving upper and lower fixed lingual retention and an upper Hawley's retainer with incorporated tongue rake.

**Treatment progress**

While there is mention here of some of the important mechanics used in this case management, note that the complete treatment progress is presented on Table 2. At the start of orthodontic management, there was need to counter the force of the tongue and to revert the crossbite, so in addition to the fixed habit breaker, anchorage was enhanced in the lower arch using a lace back to the canine ligature and bend back of the lower wire to forestall any labial pulling force. On the second visit minimal force is added to retract the lower anterior teeth, help correct the cross bite and improve/correct the class III molar relationship. This was done using a unique elastic placement method that combines the effect of cross-elastics and class III elastics placement methods named **Class III-Cross-Elastics methods**. This method requires the placement of lingual buttons on the maxillary first premolars and hooks (Kobayashi ties) on the mandibular lateral incisors. Then inter-arch elastics was used to connect the lingual buttons on each maxillary first premolar to the corresponding hooks on the mandibular canine and lateral incisor. This was done on both the left and right sides. It achieved the objective within six weeks and was discontinued. In some cases, partial and interrupted power chains were used for space closure in addition to ligature ties for anchorage to reduce and resist unwanted excessive forces on the periodontally short-changed mandibular incisors.

**Table 2: Treatment progression**

Work Done	Time
-referral to restorative -referral to periodontist	
Set up U/L arches, U 012 NiTi + L 012 NiTi, <b>Tongue rake, bend back lace back of the lower</b>	DAY 1
U 014 NiTi + L 014 NiTi	1st Visit
U 016 NiTi + L 016 NiTi, Tongue rake damaged, <b>lingual buttons placed on 14 and 24, bite pads on 36 and 46, class III/ cross elastics prescribed</b>	2nd Visit
U 016 NiTi + L 016 NiTi, Tongue rake delivered, class III/ cross elastics cont'd	3rd Visit
U 018 NiTi + L 018 NiTi, Lingual buttons, bite pads on 36 and 46, class III/ cross elastics <b>all discontinued</b>	4th Visit
U 0.20 NiTi + L 0.020 NiTi	5th Visit

U 0.20 NiTi + L 0.020 NiTi, <b>bend back, lace back of the lower discontinued</b>	6th Visit
U 0.20 NiTi + L 0.020 NiTi, <b>Tongue tamers used to replace tongue rake</b>	7th Visit
U 019 x 025 NITI + L 019 x 025 NITI	8th Visit
U 019 x 025 SSW + L019 x 025 SSW, <b>Ligature ties used away from residual spaces for e-chain</b>	9th Visit
U 019 x 025 SSW + L019 x 025 SSW, Ligature & e-chain maintained	10th Visit
U 019 x 025 SSW + L019 x 025 SSW, Ligature & e-chain maintained	11th Visit
U 019 x 025 SSW + L019 x 025 SSW, Ligature & e-chain maintained	12th Visit
U 019 x 025 SSW + L016 NITI, Brackets rebounded 34 and 45	13th Visit
U 019 x 025 SSW + L019 x 025 NITI	14th Visit
U 019 x 025 SSW + L016 NITI, Brackets rebounded 35, 44 and 45	15th Visit
U 019 x 025 SSW + L019 x 025 NITI	16th Visit
U 019 x 025 SSW + L019 x 025 SSW, Ligature ties & e-chain maintained	17th Visit
U 019 x 025 SSW + L019 x 025 SSW, Ligature ties & e-chain maintained	18th Visit
U 016 NiTi + L 016 NiTi	19th Visit
Patient debonded + Retention	20th Visit

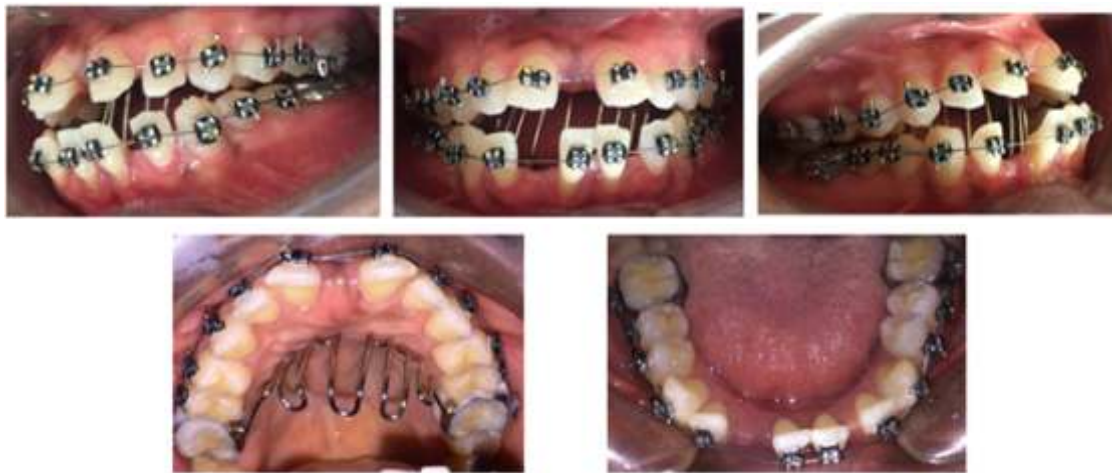

Figure 6a: Treatment progress photographs. Set-up

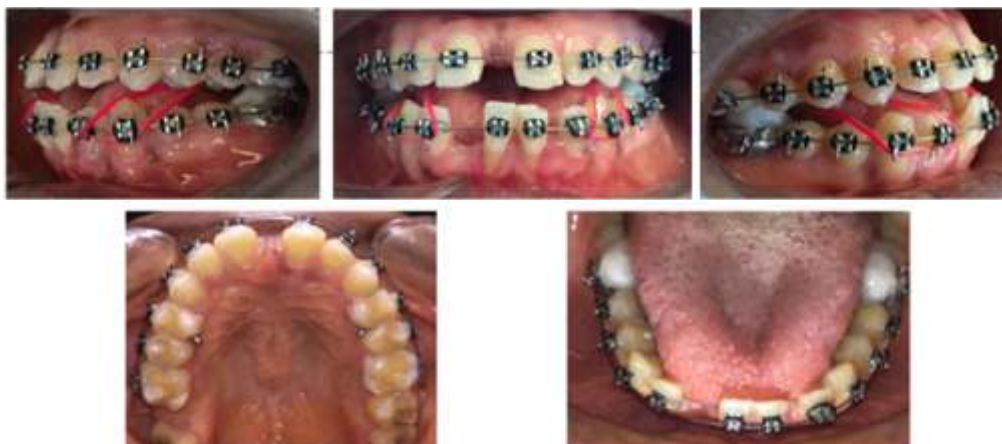

Figure 6b: Treatment progress photographs. Use of Class III-Cross-Elastic (inter-arch) method.

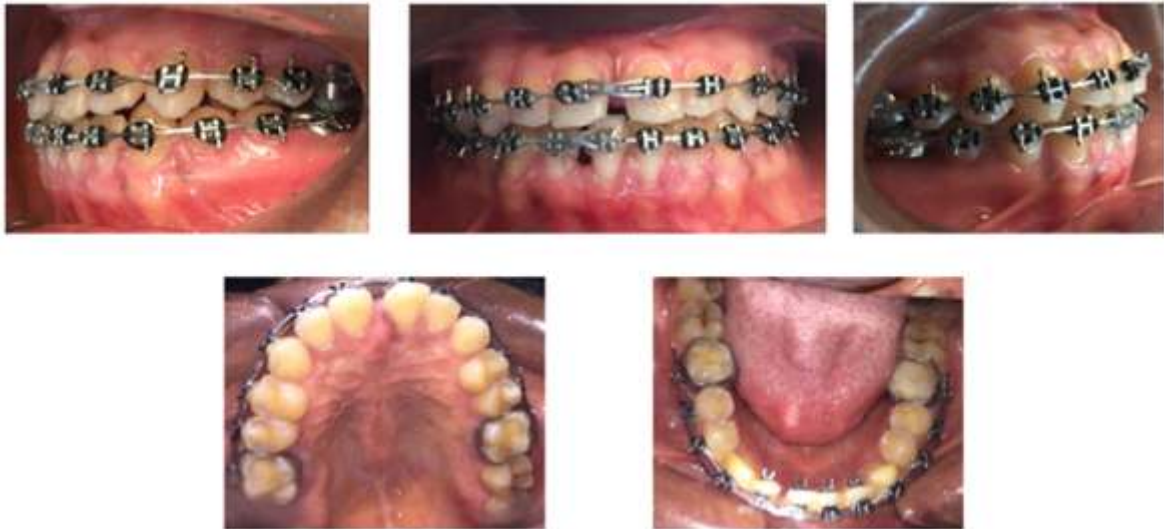

Figure 6c: Treatment progress photographs. Space closure using power-chains

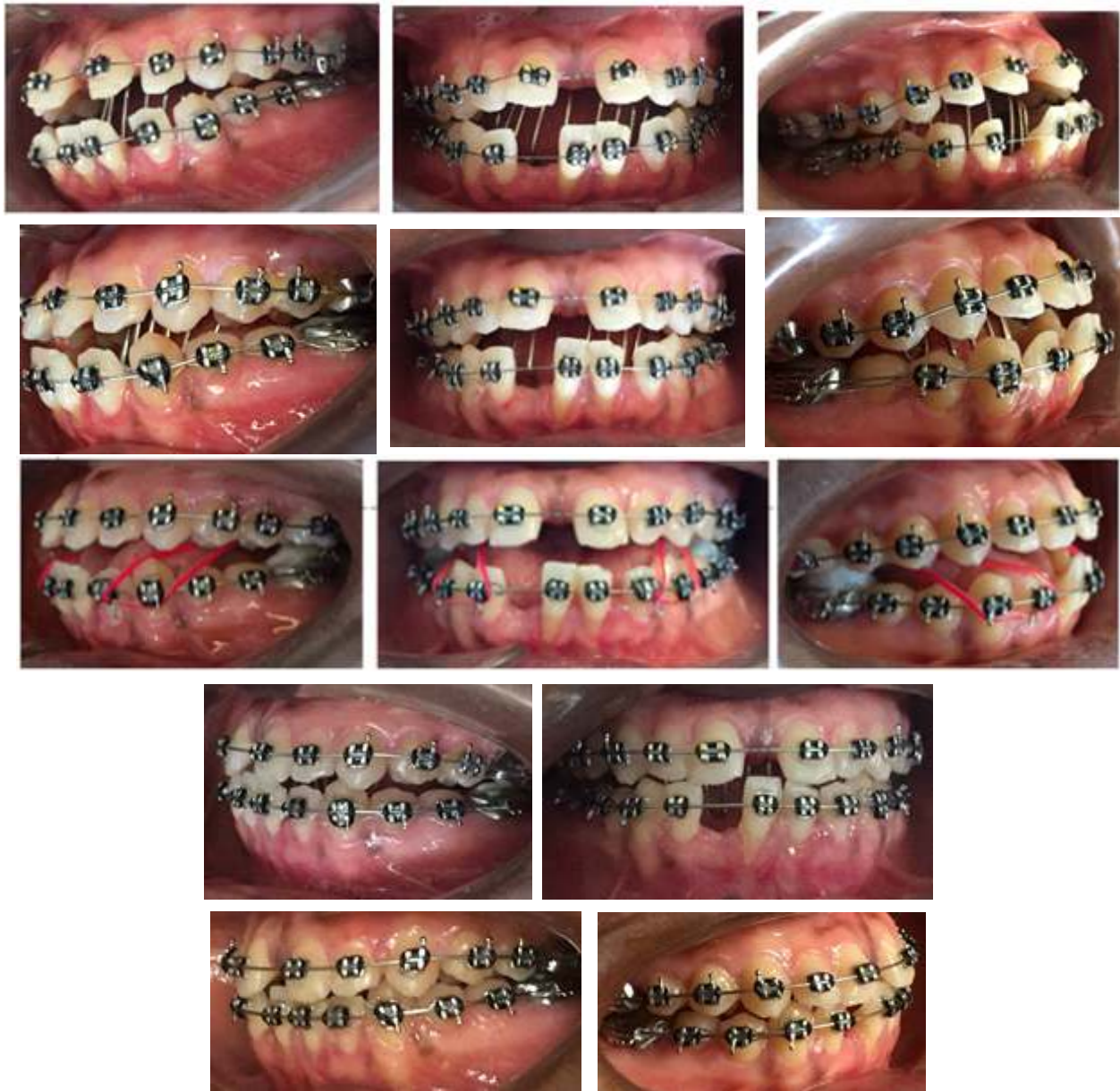
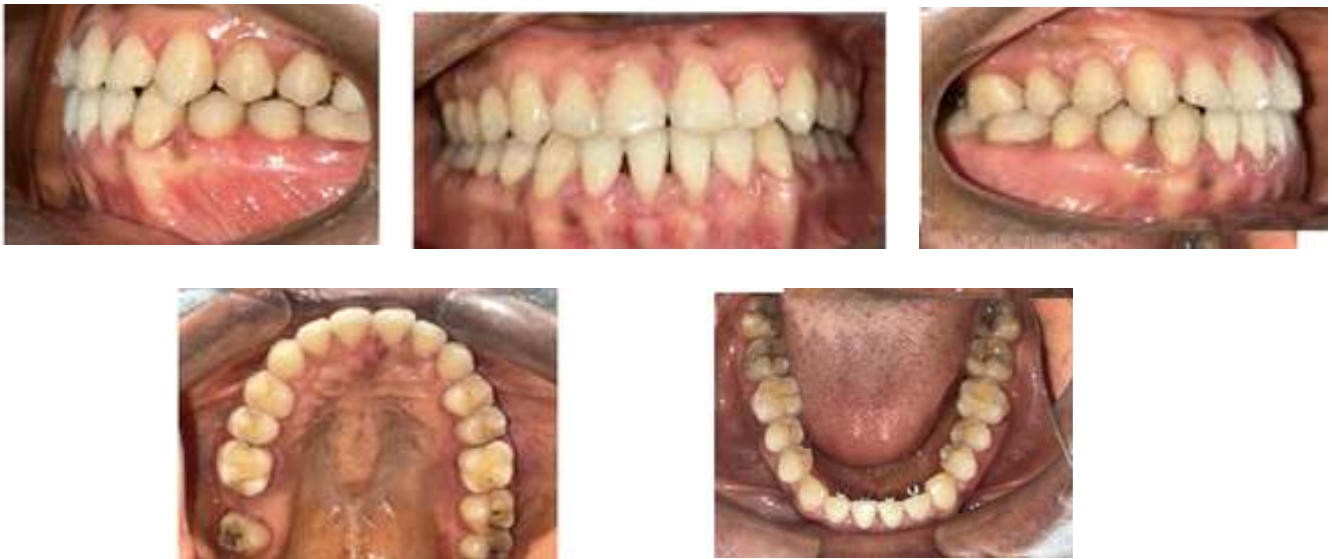
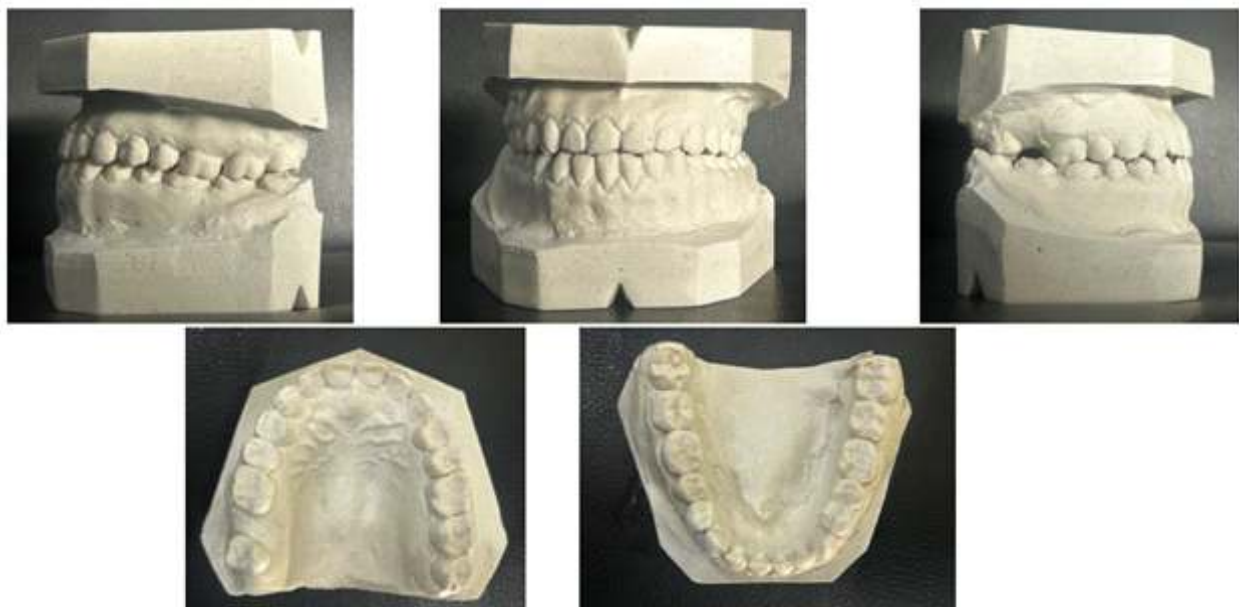Figure 6d: Treatment progress snap-shorts photographs.



**Figure 7: Posttreatment Extraoral photographs**



**Figure 8: Posttreatment Intraoral photographs**



**Figure 9: Posttreatment study models**

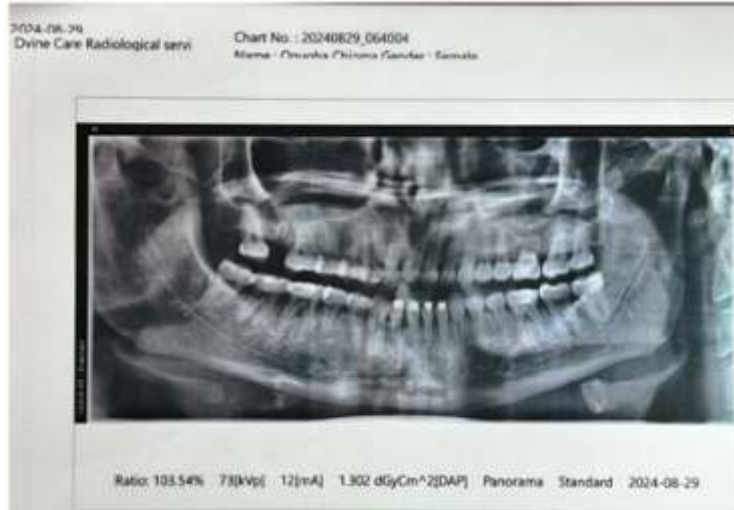
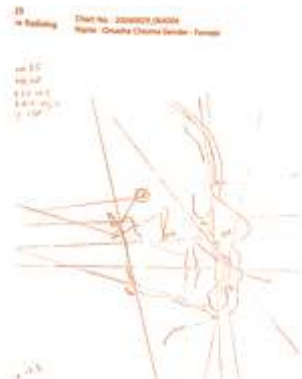
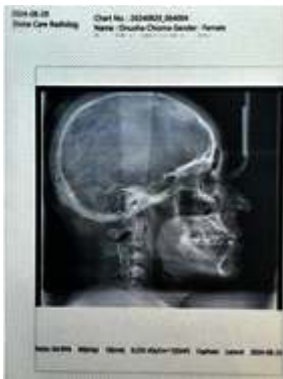Figure 10: Posttreatment panoramic radiographs



MEASUREMEN	PRE-TREATMENT (°)	POST-TREATMENT (°)
T		
SNA	83°	85°
SNB	91°	90°
ANB	-8°	-5°
SKP	3	3
WITT	-11 mm	-10.8 mm
UI-FP	136°	126°
LI-MP	103°	85.5°
IIA	103°	130°
FMA	19°	18.5°
LFH	60%	59%

Parameter	Pretreatment values	Post treatment value	Ref value
UL- E plane	-2mm	-3mm	3.21 ± 2.69
LL- E plane	+3mm	+0mm	6.76 ± 2.83
Nasolabial angle	73°	95°	84.35° ± 13.71°
H angle	17°	12°	7°-15°
Z angle	74°	77°	71°-89°

Figure 11: Posttreatment lateral cephalometric analysis

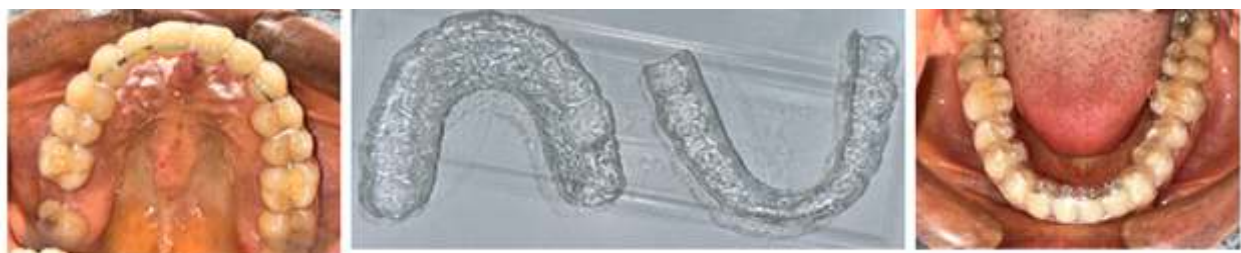
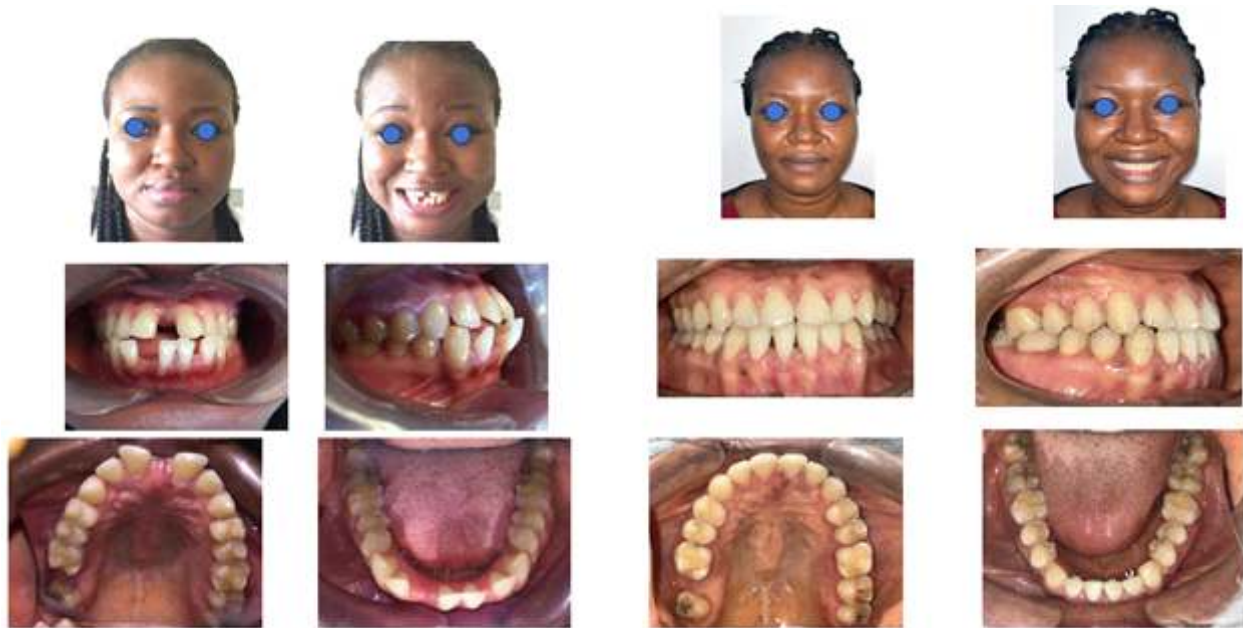

Figure 12: Posttreatment retention



**Figure 13: Treatment outcome comparison**

### Discussion

Psychosocial impact of class III malocclusion, which may result from the compromised facial aesthetics, in addition to the functional disturbances, which is mostly proportional to the magnitude of the discrepancy in these class III malocclusion cases, motivates individuals to seek orthodontic correction.<sup>11,19</sup> In this report the patient's complain was "I don't like the arrangement of my teeth and you cannot catch me smiling on camera", this means that aesthetic considerations was her major motivation factor.

The patient, a 35-year-old female has attained full maturity hence excluding the possibility of growth modification as a treatment option. The choice for orthodontic camouflage as against orthognathic surgery based orthodontic intervention was due to the patient's peculiar case assessment.

The patient's extraoral assessment revealed a concave facial profile that corresponds with the class III skeletal pattern on examination of the skeletal bases. The facial profile and skeletal pattern were confirmed by cephalometric analysis. The relative positions of the skeletal bases in relation to the base of the skull was markedly significant and consistent with a pattern III with ANB angle of  $-8^\circ$  ( $2^\circ$  to  $4^\circ$ ) and supported by a markedly significant Witt's analysis of  $-11\text{mm}$  ( $+2\text{mm}$  to  $-2\text{mm}$ ). Separate assessment of the skeletal bases showed that maxillary skeletal base  $83^\circ$

( $85.5^\circ \pm 3.5^\circ$ ) was orthognathic while the mandibular skeletal base  $91^\circ$  ( $82.7^\circ \pm 3^\circ$ ) was significantly prognathic. This prognathic mandible was supported by anterior or horizontal growth pattern of the mandible in addition to closed bite pattern and counter clockwise rotation of the jaws as affirmed by FMA, Y-Axis and Jarabak ratio results of  $19^\circ$  ( $24^\circ$ - $26^\circ$ ),  $51^\circ$  ( $53^\circ$ - $66^\circ$ ) and  $68.5\%$  ( $62\%$  to  $65\%$ ) respectively. This is consistent with a Skeletal classification type B and Dental Classification (Dewey) type C<sup>12</sup>.

The above parameters have so far been consistent with classical Class III malocclusion, but when compensation of occlusion due to the malocclusion takes its course one expects the maxillary labial segment to be proclined and their mandibular counterpart to be retroclined. In this case while the maxillary anterior teeth proclination,  $136^\circ$  ( $119^\circ$  to  $127^\circ$ ) is in line with the expected dental compensation, the mandibular counterpart was normal,  $103^\circ$  ( $96^\circ$ - $104^\circ$ ).

This patient's case was however complicated by severe labial segment spacing of 11mm on the mandible and 9mm on the maxilla. This may be as a result of the patient's tongue sucking habit that in this case has in addition to the horizontal and counter clockwise growth pattern resulted in a crossbite of all the anterior segment. This may also be accentuated by the high attachment of the maxillary and mandibular labial frena, which in addition to the

tongue habit has also resulted to gingival recession and grade I mobility of teeth.

The treatment for most borderline mild to moderate class III malocclusion was orthodontic camouflage. This is a procedure that in some cases selectively entails extraction some teeth (especially mandibular premolar teeth), class III elastics and TAD assisted distalization of the mandibular teeth.

Despite the convincing skeletal components of this patient's class III malocclusion, the excessive spacing recorded in the anterior segment of both arches, resulting in arch width discrepancies which was more prominent in the mandible, and possible aetiologic impact of the Tongue and labial frena, there was therefore need for a patient tailored treatment planning.

This case was treated as a multidisciplinary one in which the Conservative dentist, the Endodontist and the Periodontist helped to prepare the mouth for fixed appliance, ensure tissues are healthy enough for to receive treatment prepare the patient for multidisciplinary treatment to enhance aesthetic and retention plan.

At this point there may be need to update the classification of Class III malocclusion to not just include the aetiologic impact of the tongue function and size to this pathologic process<sup>20</sup> but to also include its management as part of procedures for effective management of Class III malocclusion

In this case the orthodontic treatment included the following;

1. Full upper and lower fixed orthodontic appliance (standard preadjusted edgewise Roth .022 x .028-in-slot prescription)
2. Incorporated fixed tongue rake.
3. Enhanced anchorage in the lower arch using a lace back to the canine ligature and bend back of the lower wire to retract the anterior segment
4. Inter-arch elastics in this case was done using a unique elastic placement method that combines

the effect of cross-elastics and class III elastics placement methods named **Class III-Cross-Elastics methods**.

In 25 weeks, which corresponds to the 20<sup>th</sup> visit of the patient, favourable results were achieved. The following were recorded

1. Improved psychosocial confidence
2. Reverse overjet/Anterior crossbite corrected
3. Closure of all Spaces
4. Expanded lower anterior arch segment was corrected
5. Alignment of dental midlines
6. Derotation of rotated teeth
7. Competent lips
8. Improved speech
9. Improved periodontal support

### Conclusion

After 25 months of management, the patient was satisfied with the aesthetic and psychosocial outcomes of management. Retention was done with both fixed and ESSIX retainers on both arches. There may be need to update the classification of Class III malocclusion to not just include the aetiologic impact of the tongue function and size to this pathologic process<sup>20</sup> but to also include its management as part of procedures for effective management of Class III malocclusion. Further work should be encouraged on the use of Class III-Cross-Elastics placement technique.

### Conflict of interest

The authors declare that they have no conflict of interest

### Funding

No funding was received for this study

### Authors' contributions

CEI conceptualized and wrote the study, while OCO and ESS reviewed the final draft.

### References

1. Alhammadi, M. S., Halboub, E., Fayed, M. S., Labib, A. & El-Saaidi, C. Global distribution of malocclusion traits: a systematic review. *Dent. Press J. Orthod.* 23, 40.e41–40. e10 (2018).
2. Yemitan TA, Oyapero AO. Prevalence of malocclusion in Africa: A systematic review and meta-analysis. *Magna Scientia Adv Res Reviews.* 2022;05(01):030–5.
3. Aikins EA, Onyeaso CO. Prevalence of malocclusion and occlusal traits among adolescents and young adults in Rivers State, Nigeria. *Odontostomatol Trop.* 2014 Mar;37(145):5-12.
4. Ajayi E.O. Prevalence of malocclusion among school children in Benin city, Nigeria. *J Med Biomed Res.* 2008;7(1&2):58-65.

5. Da Costa O. O. The prevalence of malocclusion among a population of northern Nigeria school children. *West Afr J Med* 1999; 18: 91-6.
6. Sanu O.O. The Epidemiology of malocclusion in Nigerians of Yoruba ethnic group. F.W.A.C.S. Thesis, Lagos University Teaching Hospital, 1994
7. Adekoya MN, Ayedun OS, Adeyemi TE. The prevalence of Malocclusion in children between the age of 10-15 years in Calabar Metropolis, Cross Rivers. *West Afr J Med.* 2021 Nov 30;Vol. 38(11);1095-1100. PMID;34922409.
8. Perez-Varela JC, Campoy MD, Lopez-Villa M, et al. Management of skeletal class III discrepancies using temporary anchorage devices. *Clin cases rev biomed considerations Sem Orthod* 2024 Dec 30; (5):572–590
9. Tweed CH. *Clinical Orthodontics*. St Louis: Mosby; 1966:715–726.
10. Park, J. U. & Baik, S. H. Classification of Angle Class III malocclusion and its treatment modalities. *Int. J. Adult Orthodon. Orthognath. Surg.* 16, 19–29 (2001).
11. Sobral MC. Compensatory treatment of angle class III malocclusion with anterior open bite and mandibular asymmetry. *Dent Press J Orthod.* 2012;17(3):138-145.
12. Maruswamy K et al. Management of class III malocclusion - A review with report of four cases. *Ann Dent Spec.* 2018 Oct;6(4);464-71.
13. Saloni P, Isha SM, Merry A, Parveen A. Treatment of Adult class III Malocclusion with Orthodontic Camouflage. A 2 Case report. *J Dent. Oral. Biol.* 2023;8:1-7.
14. Troy BA, Shanker S, Fields HW, Vig K, Johnston W. Comparison of incisor inclination in patients with Class III malocclusion treated with orthognathic surgery or orthodontic camouflage. *A m J Orthod Dentofac Orthop.* 2009;135(2):146–7.
15. Sarangai H, Namdev R, Garg S, Saini N, Singhai P. Treatment modalities for early management of class III skeletal malocclusion: a case series. *Contemp clin dent.* 2020 Jan 1;11(1):91-6.
16. Carriere L. Nonsurgical correction of severe skeletal class III malocclusion. *J Clin Ortho.* 2016 April;50(4):216-30.
17. Baik HS. Limitations in orthopaedic and camouflage treatment for Class III malocclusion. *Sem Orthod.* 2007;13(3):158–74.
18. Liou EJ, Wang YC. Orthodontic clockwise rotation of maxillomandibular complex for improving facial profile in late teenagers with Class III malocclusion: A preliminary report. *APOS Trends Orthod* 2018;8:3-9.
19. Bittencourt MA. Early treatment of patient with Class III skeletal and dental patterns. *Dental Press J Orthod.* 2015;20(6):97–109.
20. Deshkar M, Thosar NR, Kabra SP, Yeluri R, Rathi NV. The fluence of the tongue on the development of dental malocclusion. *Cureus.* 2024 may 29;16(5):e61281. Doi:107759/cureus.61281. PMID 38947580; PMID: PMC11211712.

Abstract Presentation at NAO 2025 Annual Scientific Conference held at the View Point Hotel and Suites, Benin City, Edo State, from September 23-27, 2025.

## ORAL PRESENTATIONS

### ABSTRACT ONE

#### Prevalence and Distribution of Dental and Occlusal Anomalies in Paediatric Patients with Endocrine Disorders at LUTH.

Adeloye AY<sup>a</sup>, Oyenusi EE<sup>b</sup>, Utomi IL<sup>b</sup>, Ibenye VN<sup>c</sup>, Alayo Mo<sup>c</sup>

<sup>a,b,c</sup> Lagos University Teaching Hospital, Department of Child Dental Health

bimsolowo@gmail.com

**Background:** Dental anomalies involve abnormalities in the number, size and shape of teeth, structural defects or eruption pattern disruptions. Endocrine disorders are associated with various dental and occlusal anomalies including enamel defects, delayed tooth eruption, changes in tooth size and position, crowding, spacing, deep bite, open bites, crossbites. The identification of dental and occlusal anomalies are important since they can cause disturbances such as malocclusion, increased susceptibility to caries and aesthetic concerns.

**Aim:** To determine the prevalence and distribution of dental and occlusal anomalies amongst paediatric patients with endocrine disorders in LUTH.

**Methods:** Cross -Sectional study conducted at the Paediatric Endocrinology clinic, LUTH. Informed consent, assent and ethical approval was obtained. Forty -Two Participants were recruited via convenient sampling technique, aged 7-18 years. Clinical examination was done with dental examination sets. Data was analyzed with p value set at <0.05.

**Results:** The prevalence of dental and occlusal anomalies was 64.3%, mean age was  $11.31 \pm 4.3$  years. Females 59.5% and males 40.5%. The frequencies of the anomalies included Crowding 11.9%, Crossbite 14.3%, Open bite 16.7%, Missing teeth 9.5%, Enamel defects 23.8%, Microdontia 2.4%, Malformed teeth 2.2%.

**Conclusion:** Dental and occlusal anomalies are prevalent and commonly distributed amongst paediatric patients with endocrine disorders. Timely identification can minimize complications and enable a more favorable prognosis.

### ABSTRACT TWO

#### Evaluation of The Maxillary and Mandibular Dental Midlines and Facial Midlines of Adolescents Aged 12-18years in Rivers State, Nigeria

<sup>a,b</sup>Ututu C , Orikpete MO , Aikins EA

<sup>a</sup>Department of Child Dental Health, University of Port Harcourt Teaching Hospital, Port Harcourt

<sup>b</sup>Department of Orthodontics and Paediatric Dentistry, Faculty of Dentistry, College of Health Sciences, University of Port Harcourt, Rivers State

Email: [chinyereututu@yahoo.com](mailto:chinyereututu@yahoo.com)

**Background and Aim:** Dentofacial symmetry is an important factor in the evaluation of dentofacial aesthetics in orthodontics. The dental midline is equally important in smile design. The aim of this study was to assess dental midline of secondary school students in Rivers State.

**Methods:** This was a cross-sectional analysis of 12- 18years old private and public secondary school students in Rivers State. SPSS version 25.0 was used for data analysis, with level of significance set at  $p < 0.05$ .

**Results:** Six hundred and ten students, comprising 212(34.8%) males and 398(65.2%) females with mean age of  $13.7 \pm 1.4$  years participated in this study. Fifty two percent of participants had dental midline coincidence while 48% had dental midline deviation. About three quarters (78.2%) had mandibular dental midline deviation, 17.4% had maxillary dental midline deviations while only 4.4% had deviations in both arches. More than half (57%) of the deviations were to the right, 42% to the left while only 1% had asymmetrical deviations in both arches. The mandibular dental midlines were deviated more to the right in 60.7% cases while majority (56.9%) of maxillary dental midlines was deviated to the left. A greater proportion (58%) of the males had dental midline deviation than the female adolescents (45.5%).

**Conclusion:** Almost half of the study participants had dental midline deviations. Most of the affected participants were males. The dental midlines of mandibles were more deviated than those of maxillae and the right side was more affected than the left.

**Keywords:** Dental midlines, Facial midlines, Adolescents, Aesthetics, Rivers State

### ABSTRACT THREE

## Evaluation of Colour Preferences for Elastic Ligatures among Orthodontic Patients in Nigeria: A Guide for Clinicians

Odebiyi O.T<sup>a</sup>, Uzamere E.O<sup>b</sup>

<sup>a</sup>Department of Orthodontics, University of Benin Teaching Hospital, Benin city, Nigeria;

University of Benin, Benin city,  
Nigeria/<sup>b</sup>Summit Dental clinics, Abuja.

Presenting Author: D r. Odebiyi Oluwaseyi

Email address: [sheyibiyi@gmail.com](mailto:sheyibiyi@gmail.com)

**Background/Aim:** Elastic ligatures, beyond their functional role, allow patients to personalize their treatment through color selection. Preferences for these colors may change over time within specific cultural contexts like Nigeria. This study aimed to evaluate elastic ligature color preferences among Nigerian orthodontic patients over time, guiding clinicians in inventory decisions and enhancing patient-centered care.

**Methods:** A prospective longitudinal observational study, conducted among patients undergoing fixed orthodontic treatment. Color preferences were recorded at treatment initiation and at six-week intervals over six months. At each visit, patients selected colors from a standardized color guide under consistent lighting. Data were analyzed using descriptive and inferential statistics.

**Results:** Silver and Black elastic ligatures were the two top most preferred colors (16.4% and 10.9% respectively) and were consistently the most preferred across all visits.

Other popular colours included shades of Blue; and Violet.

Preferences evolved over time, with brighter colors gaining popularity. Gender differences were statistically significant, with females preferring bright colors while males favored neutral tones. Age-related differences were

significant only at early visits ( $p < 0.01$ ). Patient enthusiasm influenced early bright color choices ( $p < 0.05$ ), though this effect decreased as treatment progressed.

**Conclusion:** Elastic ligatures preferences among Nigerian orthodontic patients are dynamic and influenced by a number of factors. Regular update of color inventory can improve patient satisfaction and minimize product waste.

**Keywords:** Elastic ligature, color, preferences, orthodontic, clinician

#### ABSTRACT FOUR

### An Audit of Factors Affecting the Duration of Orthodontic Treatment by Residents at Lagos University Teaching Hospital

Ayenakin O,<sup>a</sup> \*\*Odah GE,<sup>b</sup> Isiekwe IG,<sup>c</sup> Umeh OD,<sup>d</sup>

<sup>e,f,g</sup>Utomi IL, daCosta OO, Sanu OO

Lagos University Teaching Hospital,  
Department of Child Dental Health.

[graceodah@yahoo.com](mailto:graceodah@yahoo.com)

**Background:** The duration of orthodontic treatment is very important to both patients and orthodontists. Prolonged treatment time not only decreases patient's compliance but also puts a strain on already limited resources, especially in resource-challenged societies like Nigeria.

**Aim:** To investigate the possible influential factors affecting the duration of orthodontic treatments carried out by senior residents at Lagos University Teaching Hospital.

**Methods:** A cross-sectional retrospective study conducted at the Orthodontics Unit, Department of Child Dental Health, Lagos University Teaching Hospital (LUTH), using records of all patients whose treatment was initiated and completed by orthodontic residents with Roth 0.022" appliances between 2018 and 2025.

**Results:** A total of 41 participants (68.3% female; mean age  $22.71 \pm 9.0$  years) were selected. Over half (56.1%) were managed by first-year senior residents and 80.5% were non-extraction cases. Treatment gaps were common; 53.7% had 1-3 months gap, while 34.1% had >3 months gap. Overall, 65.9% had treatment durations >24 months, while 34.1% completed treatment within 24 months. There was a statistically significant ( $p < 0.05$ ) association between the residents' level of training, treatment gaps, extraction cases, and treatment duration.

**Conclusion:** This study showed that lack of experience in the early stages of residents' training, complex cases, and lack of consistency with clinic attendance by patients prolonged treatment time at LUTH

#### ABSTRACT FIVE

### Clear Aligner Therapy in Nigeria: Awareness, Training and Clinical Practice Patterns among Dental Practitioners

Aiyebomwan JO,<sup>a</sup> Uzamere EO,<sup>b</sup> Ize-Iyamu In<sup>a</sup>

<sup>a</sup>Department of Orthodontics, University of Benin Teaching Hospital, Benin city, Nigeria;

<sup>b</sup>University of Benin, Benin city, Nigeria/Summit Dental clinics, Abuja.

**Background And Aim:** Clear aligner therapy has gained global popularity in recent years, but its adoption and integration in clinical practice may vary by region. This study evaluates the awareness, training, and clinical application of clear aligners among dental practitioners in Nigeria.

**Methods:** A pilot survey was conducted among 120 dental practitioners. Data were collected through a structured questionnaire addressing demographics, knowledge of clear aligners, sources of training and clinical use of clear aligners. Descriptive statistics were used to analyze responses.

**Results:** Awareness of clear aligners was high (96.5%), with conferences and peer discussions among colleagues being the main sources of information (54.3% each). Only 31 respondents (26.7%) reported acquiring the knowledge from dental school. Although 57.8% were aware of aligner training programs, only 24.1% had undergone such training. Only 33.6% of respondents currently use aligner therapy. Among these, most were trained via certification courses (66.7%), had less than 3 years of experience (77.0%), and mostly used the Invisalign brand (97.4%). The common indications included mild spacing (89.7%), mild crowding (84.6%) and open bite (53.8%). The major barriers among nonusers included lack of training (38%) and cost (15.2%), however, 79.7% expressed willingness to undergo training.

**Conclusion:** While awareness of clear aligners among dental practitioners in Nigeria is high, clinical adoption remains limited due to insufficient training and experience.

**KEYWORDS:** Clear aligners, Invisalign, orthodontics, dental practitioners, clinical practice

## ABSTRACT SIX

### From Braces to Business: Building A Scalable Orthodontic Practice without Losing A Clinical Soul.

Amy Shumbusho  
Founder & Clinical Director, Smile 360 Dental Specialists, Lagos  
Email: [info@smile360ng.com](mailto:info@smile360ng.com)

**Background and Aim:** While clinical mastery remains the foundation of orthodontics, the long-term success of any practice depends increasingly on sustainable business systems, patient-centric innovation, and leadership evolution. This presentation shares the Smile 360 journey from a single-chair practice to a multi-million dollar brand and offers a framework for scaling orthodontic care without compromising clinical values.

**Methods:** Drawing on 15+ years of clinical entrepreneurship and 30 years + as a clinician, this case based analysis explores the strategic pillars that supported Smile 360's growth: digital workflow integration, brand positioning around smile design, patient experience innovation, and structured team development. Emphasis was placed on adopting systems thinking, aligning vision with structure, and developing internal leaders to drive continuity and succession.

**Results:** Over a decade, Smile360 has grown into a leading orthodontic and cosmetic dental brand in West Africa. Key outcomes include increased aligner adoption, high patient retention, optimized treatment efficiency through digital tools, and team-led practice expansion.

**Conclusion:** The evolution from clinician to clinical entrepreneur is not a detour, it is a deepening of impact. For orthodontists to pioneer the future, we must master the art of building practices that are not only clinically excellent but also structurally resilient, brand-aware, and legacy-minded. This session will empower colleagues to lead with both heart and systems.

**Keywords:** Orthodontic business, practice growth, clinical entrepreneurship, digital workflows, succession planning

## ABSTRACT SEVEN

### Determination of Arch Width in Pretreatment Orthodontic Patients in a Tertiary Health Facility

Otaren NJ<sup>a</sup>, Osadiaye He<sup>b</sup>

<sup>a</sup>Department of Orthodontics, University of Benin/University of Benin Teaching Hospital

<sup>b</sup>Department of Orthodontics University of Benin Teaching Hospital

Email: hopeosayi@gmail.com

**Background:** Human dental arches can be normal, wide or narrow. The intercanine and intermolar arch widths are established after eruption of canine and molars in the dental arches. Assessment of dental arch dimensions is an important diagnostic criterion in orthodontic diagnosis, treatment planning and post treatment stability.

**Objective:** The aim of this study was to determine mean intercanine and intermolar arch width in Angle's class I, malocclusion. To determine sexual dimorphism and effect of early and late permanent dentition on the dental arch width.

**Methods:** Pre-treatment maxillary and mandibular dental 150 pairs of casts of orthodontic patients of the University of Benin Teaching Hospital were used for this study. Maxillary and mandibular intercanine arch width and intermolar arch width were measured with digital caliper.

**Result:** 150 pairs of dental casts was used in the study. The mean age of the study participants was 17.92 ( $\pm 9.050$ ) years. 62.6% were females. The mean maxillary inter-canine and inter-molar widths were  $34.38 \pm 3.817$  mm and  $39.92 \pm 3.671$  mm, respectively, the corresponding mandibular values were  $27.02 \pm 3.036$  mm and  $34.13 \pm 3.580$  mm.

**Conclusion:** The study showed sexual dimorphism with male casts having greater maxillary and mandibular inter-canine and inter-molar widths compared to female casts.

**Keywords:** Dental Arch Width, Malocclusion

## ABSTRACT EIGHT

### Pattern of Dental Anomalies seen On Panoramic Radiographs of Patients Attending Orthodontic Clinic at University Of Nigeria Teaching Hospital, Enugu

Ndukwe Anne NI, Okeke Azubuike CI, Nzekwe Chioma MI, Okeke Chinonso I

Department of Child Dental Health. University of Nigeria Teaching Hospital, Ituku Ozalla, Enugu  
annendukwe@yahoo.com

**Background:** Dental anomalies refer to developmental disturbances that affect number, size, shape, structure or position of teeth, These deviations from normal tooth development may result in irregular alignment and malocclusion which can compromise both function and aesthetics often needing orthodontic or restorative intervention.

**Aim:** To determine the prevalence of developmental dental anomalies on panoramic radiographs of patients attending the Orthodontic clinic at University of Nigeria Teaching Hospital.

**Methods:** This was a retrospective cross sectional study in which panoramic, radiographs of patients who presented to the orthodontic clinic from 2021-2025 were assessed for the presence of dental anomalies. The anomalies assessed were, supernumerary teeth, hypodontia, oligodontia, Transposition and mesiodens. Data analysis was carried out with SPSS version 23 with results summarized in tables and frequency distributions

**Results:** A total number of 185 radiographs of patients were reviewed. There were 110 females and 75 males. Forty six patient's radiographs (24.8%) had dental anomalies and a total of 86 dental anomalies were recorded from these radiographs. These anomalies included, Impaction 63 (72.4%), Supernumerary teeth 12 (13.8%), Transposition 5 (5.5%), Hypodontia 5 (5.75%) and mesiodens 2 (2.3%).

Fifty four (62.1%) dental anomalies were seen in the mandible while 33 (37.9%) anomalies were seen in the maxilla. More females had dental anomalies than males.

**Conclusion:** Impaction was the most common dental anomaly observed. They were more common in the mandible than the maxilla and female patients were more frequently affected than males. These findings highlight the importance of routine radiographic evaluation for early detection and timely intervention in orthodontic patients

**Keywords:** Dental anomalies, Maxilla, Mandible, Developmental, Radiograph

## ABSTRACT NINE

### Cephalometric Evaluation Of The Soft Tissues Following Orthodontic Treatment.

1 1 1 1 Umeh OD , daCosta OO , \*Nnodebe HA, Odah GO, Ayenakin OI  
Lagos University Teaching Hospital, Department of Child Dental Health  
EMAIL: hopeakor76@yahoo.com

**Background:** Orthodontic treatment aims to improve the aesthetic and functional aspects of the dentofacial complex. The determination of facial aesthetics is influenced by both the dentoskeletal tissue and the underlying soft tissues. Cephalometric assessments are valuable for soft and hard tissue evaluation in orthodontic treatment planning and outcome.

**Aim:** This study evaluated the changes in soft tissue parameters following fixed orthodontic treatment using cephalometric analysis.

**Methods:** A cross-sectional retrospective study. The study population comprised patients who had completed their orthodontic treatment in the Lagos University Teaching Hospital over one year. Their pre-treatment and post-treatment cephalograms were manually traced to compare pre- and post-treatment linear and angular soft tissue measurements. Statistical analysis was carried out using the Statistical Package for Social Sciences, SPSS version 26.0. The level of significance was set at  $P=0.05$ .

**Results:** A total of 47 patients with 94 cephalometric radiographs were recruited for the study. The male-to female ratio was 1:2.1. Extraction cases comprised 14.9% while non-extraction treatments were 85.1%. There was no statistically significant difference between the pre and post-treatment soft tissue cephalometric values in both males and females, as well as the extraction and nonextraction treatment ( $p<0.05$ )

**Conclusion:** Fixed orthodontic treatment showed no significant soft tissue changes in both extraction and nonextraction cases.

**Keywords:** CEPHALOMETRIC RADIOGRAPH, ORTHODONTICS, SOFT TISSUE, EXTRACTION

## ABSTRACT TEN

### Evaluation of Dental Age and Skeletal Maturation in A Patient Population with Repaired Cleft Lip and Palate, Aged 5-16 Years Old.

Koledoye OA, daCosta OO, Isiekwe IG, Sanu OO  
Department of Child Dental Health, Lagos University Teaching  
Hospital. motundebiola@gmail.com

**Background:** Children with clefts usually have skeletal discrepancy and compromised aesthetics resulting in orthodontic treatment need. Growth modification is important in the orthodontic management of patients with clefts and this is best achieved during the peak growth period. Also, the best timing for orthognathic surgery is dependent on the remaining growth potential. A good understanding of the dental and skeletal ages is important in the treatment planning and success in patients with clefts.

**Objectives:** To assess and compare dental age and skeletal maturity in children with non-syndromic UCLP and in children without clefts using Demirjian and Baccetti methods respectively.

**Methods:** Fifty children with UCLP and fifty non-cleft children with chronological ages 5 to 16 years were assessed. Each study group was matched for age and sex. The participants panoramic and lateral cephalometric radiographs were assessed to determine the dental age and cervical ver tebrae maturation stages. Mean comparison of numerical variables was assessed using independent t-test. Statistical significance was inferred at  $p < 0.05$ .

**Results:** The dental age was significantly ahead of the chronological age in both cleft and non-cleft groups. However, there was a delay in the dental age in the cleft group when compared with the non-cleft group, however, this difference was not significant ( $p$ -value = 0.407). At ages 8.1-12.0 years, during CVM 3 and 4, (peak period) the patients without cleft attained skeletal maturity earlier than children with UCLP. However, by age 12-16 years, both groups matched in skeletal maturity. There was a positive association between dental age and skeletal maturity in the cleft and non-cleft groups.

**Conclusion:** The non-cleft participants attained peak skeletal maturity significantly earlier than children with UCLP. This needs to be considered when timing orthodontic treatment in patients with clefts.

## ABSTRACT ELEVEN

### Craniofacial Morphology and Risk of Obstructive Sleep Apnoea in Adolescent Orthodontic Patients: A Cephalometric Evaluation

Odunsi OYI<sup>a</sup>, Yemitan TA<sup>b</sup>, daCosta Oo<sup>c</sup>

<sup>a</sup>Department of Child Dental Health, Lagos State University Teaching Hospital, Ikeja.

<sup>b</sup>Department of Child Dental Health, LASUCOM/Lagos State University Teaching Hospital, Ikeja.

<sup>c</sup>Department of Child Dental Health, Faculty of Dental Sciences, CMUL/Lagos University Teaching Hospital.

Corresponding author: Dr Omolara Odunsi,  
laranig@yahoo.com

**Background and Aim:** Obstructive sleep apnoea (OSA) is a multifactorial sleep disorder affecting all age groups. Its pathogenesis is linked to structural craniofacial anomalies, as well as factors such as obesity and male

gender. The study aimed to assess the risk of OSA in adolescent orthodontic patients using the modified STOP Bang questionnaire and to evaluate its association with craniofacial morphology.

**Methods:** A prospective, comparative study was conducted among 46 adolescent orthodontic patients at the Lagos State University Teaching Hospital. Participants were screened for OSA risk using the modified STOP-Bang questionnaire and categorized into control (n=23) and test (n= 23) groups based on risk scores. All subjects underwent clinical evaluation and hard tissue lateral cephalometric radiographic analysis using FACAD® software. Data were analysed using SPSS® version 22.

**Results:** The mean age of participants was  $15.22 \pm 2.0$  years. Among those at risk, (test group) 13% (n = 6) had a high risk and 37% (n = 17) an intermediate risk of OSA.

Cephalometric analysis revealed significant associations between OSA risk and reduced SNB angle, reduced Sn-Go-Gn, and increased N-S-H angle.

**Conclusions:** Mandibular retrognathia, reduced mandibular plane angle, and inferior hyoid bone positioning were significantly associated with increased OSA risk.

**Keywords:** Obstructive sleep apnoea, Craniofacial, Cephalometry, Modified STOP Bang Questionnaire

## ABSTRACT TWELVE

### Mandibular Canines' Transmigration and Ectopia along the Midline: Case Series and Literature Review

Orikpete MO<sup>c</sup>, Ojebor HS<sup>a</sup>, Adekoya MN<sup>a</sup>, Bassey GO<sup>a</sup>, Imasuen H<sup>b</sup>, Bassey Es<sup>a</sup>

<sup>a</sup>Department of Child Dental Health, Faculty of Dentistry, College of Medical Sciences, University of Calabar, Calabar, Nigeria

<sup>b</sup>Department of Prosthodontics, Faculty of Dentistry, College of Medical Sciences, University of Calabar, Calabar, Nigeria

<sup>c</sup>Department of Child Dental Health, Faculty of Dentistry, University of Port-Harcourt Teaching Hospital, Rivers State, Nigeria

**Background and Aim:** Ectopic eruption of mandibular canines is an uncommon clinical finding, with a reported prevalence ranging from 0.08% to 1.29%. Unlike their maxillary counterparts, mandibular canines rarely present ectopically, yet when they do, they may exhibit atypical migration patterns such as transmigration or transposition. These cases pose diagnostic and therapeutic challenges, especially in resource-limited settings. This study reports three presentations of ectopic mandibular canines and their management by observation, extraction, or orthodontic correction.

**Methods:** Three patients presenting with midline-displaced mandibular canines were evaluated through clinical and radiographic examinations. Each case was classified according to established systems (Mupparapu's classification for transmigration; Rai's classification for transpositions).

Management was tailored to tooth position, space, esthetics, function, age, resources, and patient preference.

**Results:** Case 1 involved a 26-year-old male with Mupparapu's Type III transmigration of the left mandibular canine, managed conservatively by observation. Case 2, a 52-year-old female, presented with Mupparapu's Type V

transmigration of the right mandibular canine, treated by extraction and orthodontic space management. Case 3, a 13-year-old female with bilateral mandibular canine-lateral incisor transpositions (Rai's Type C), underwent fixed orthodontic treatment supported by temporary anchorage devices, achieving progressive alignment.

**Conclusion:** Ectopic mandibular canines present with variable clinical patterns requiring case-specific diagnosis and tailored interventions. Observation, extraction, and orthodontic realignment all represent viable

management options, with the choice guided by tooth position, space availability, esthetics, and patient-centered factors. This case series underscores the importance of early diagnosis, appropriate classification, and patient-centered decision-making in optimizing outcomes for ectopic mandibular canines.

**Keywords:** Ectopic mandibular canine, transmigration, transposition, orthodontic management, case series

## ABSTRACT THIRTEEN

### Knowledge, Perception and Attitude of Patients towards use of Artificial Intelligence in Orthodontic Treatment: Awareness and Privacy Concerns.

1 2 3 4 Awwal NM , Sanu OO , Isiekwe IG, Odah GE, Ayenakin O.  
Lagos University Teaching Hospital, Department of Child Dental Health.  
E Mail: beelah.mimi@gmail.com

**Background:** Artificial intelligence (AI) is increasingly being integrated into orthodontic practice, offering potential benefits in diagnosis, treatment planning, and patient monitoring. Patient's acceptance depends on their knowledge, perception, and attitude toward such technologies.

**Aim:** Assessment of Patients, Knowledge, Perceptions, and Attitudes to AI-Integrated Treatment in Orthodontics.

**Methods:** Cross-sectional survey was conducted among 135 patients attending orthodontic clinics in Lagos, Nigeria. A structured questionnaire assessed demographic characteristics, knowledge of AI in orthodontics, perceptions of its benefits, risks, and attitudes toward its integration. Data were analyzed using descriptive statistics.

**Results:** Knowledge of AI was high, 80% recognizing its potential to aid diagnosis, reduce human error, and personalize treatment. 62% expressed willingness to accept AI-assisted care under orthodontist supervision, 65–70% reported concerns regarding data privacy, security, and liability for errors. Younger, more educated respondents, those with prior orthodontic treatment, demonstrated greater acceptance of AI integration. Respondents were predominantly female (80%), 21–30 years (50%), with most having tertiary education (90%) and prior orthodontic experience (75%).

**Conclusion:** Patients showed strong awareness of AI's potential benefits in orthodontics but maintained caution due to trust, ethical, and privacy concerns. Targeted education, especially the need for further research into specific privacy-enhancing AI features or patient-provider communication strategies. This may enhance acceptance and facilitate safe, ethical adoption of AI in orthodontics.

## ABSTRACT FOURTEEN

### Patient Centric Mindset in Orthodontic Practise

Ernest MA  
University of Ilorin Teaching Hospital  
[Email: ernest.ma@unilorin.edu.ng](mailto:ernest.ma@unilorin.edu.ng)

**Keywords:** Patient- Center, Mindset, Patient Satisfaction, Orthodontics

**Background And Aim:** Patient – Centric Mindset means prioritizing patient's need in every operational (clinical/research) and strategic decisions. The orthodontist should not only be an expert in the use of diverse treatment

modalities and the latest technology, but he or she must also manifest honesty, empathy, compassion, altruism, and respect to the dignity and beliefs of the patients and their families.

Various researches have found that the doctor-patient relationship was the most important factor contributing to patient satisfaction. Patient-centered treatment is based on assessing patient experience, patient reported outcomes and patient satisfaction. Achieving patient satisfaction comes with a lot of challenges in our environment as we are cumbered with excessive work load due to the JAPA Syndrome that has led to reduced workforce coupled with the harsh economic and work environment. The pull and push factors are discussed.

What can be done to make patients more satisfied?

Adopting a culture of responsibility, taking charge to deliver results, willingness to take up small task, recognizing your role is significant, taking ownership and being dedicated to assignments.

**Conclusion:** At the heart of making shift to patient centered mindset is a commitment to excellence, efficiency and high productivity ensuring that every patient enjoys seamless Orthodontic care experience. Thus, the true art in orthodontic care is to establish a cooperative relationship with the patient through effective communication, critical thinking, and empathetic behavior.

## POSTER ONE

### Esthetic Appeal of Fixed Orthodontic Appliances: A Multi-centre Nigerian Study

Ojebor HS, Adekoya MN , Bassey GO , Osadiaye HE

<sup>a</sup>Department of Child Dental Health, Faculty of Dentistry, College of Medical Sciences, University of Calabar, Calabar, Nigeria

<sup>b</sup>Department of Orthodontics, University of Benin Teaching Hospital, Benin City, Edo State, Nigeria

Email: hopeosayi@gmail.com

**Background and Aim:** Aesthetic concerns increasingly shape orthodontic appliance design, with options such as ceramic brackets, lingual appliances, and clear aligners reducing the visibility of metal braces. At the same time, the rise of “fashion braces” highlights varied perceptions of orthodontic aesthetics. This study assessed the esthetic appeal of fixed appliances among Nigerian patients and examined the influence of sociodemographic factors.

**Methods:** A cross-sectional survey was conducted among patients on fixed appliance therapy in three southern Nigerian teaching hospitals. A structured questionnaire captured demographics, treatment characteristics, and aesthetic perceptions. Associations were tested using Chisquare or Fisher's Exact Test ( $p < 0.05$ ).

**Results:** A total of 182 patients (mean age  $21.17 \pm 8.08$ ; 59.0% female) participated. More than half (59.9%) found braces esthetically pleasing, and 73.1% reported improved self-esteem. Braces were perceived as fashionable by 53.3%, while 80.2% anticipated debonding; only 27.5% wished to retain braces after alignment. One-quarter (25.0%) would consider braces purely for fashion, with significant variation by treatment facility ( $p = 0.004$ ) but not age or gender. Those considering braces for fashion were more likely to find them esthetically pleasing ( $p = 0.002$ ). Positive esthetic perception was also associated with believing benefits outweighed oral hygiene challenges ( $p = 0.002$ ) and discomfort ( $p = 0.024$ ) but not cost or diet.

**Conclusion:** Most orthodontic patients in southern Nigeria regard braces as esthetically appealing and self-esteem enhancing. Perceptions are influenced by treatment facility, fashion considerations, and tolerance of treatment challenges, underscoring the importance of integrating esthetic concerns into orthodontic care planning.

**Keywords:** Orthodontics, Esthetic appeal, Fixed appliance, Braces, Patient perception, Nigeria

## POSTER TWO

### Community Engagement and Dental Outreach in An Underserved Community

<sup>a</sup>Tokunbo Abigail Adeyemi

Senior Academic and Director Sam-Alpha Limited

Email address [tokunbo.abigail@samalphalimited.com](mailto:tokunbo.abigail@samalphalimited.com)

<sup>b</sup>Omotayo Francis Fagbule

Senior Lecturer, University of Ibadan, Ibadan, Nigeria.

Email address: [ffagbule@gmail.com](mailto:ffagbule@gmail.com)

Correspondence Address

Dr Tokunbo Adeyemi

Correspondence email address: [ta.adeyemi@ui.edu.ng](mailto:ta.adeyemi@ui.edu.ng)

**Background:** The World Health Organisation Global Oral Health Action Plan 2023-2030 has outlined six major goals to include people centred oral care. Community Dental Outreach and engagement allows dental professionals to work with people within a community to improve oral health access and outcomes. Orthodontists are dental professionals that can volunteer to work in underserved communities. This study presents statistics from a series of community outreaches in a selected underserved community

**Methodology:** The following data were collected on a spreadsheet; age, gender, socio-economic status, significant lifestyle relevant to oral health, presenting complaint, type of intervention done, type of treatment received. Data collected was analysed using a computer software.

**Results:** Five hundred people (500) attended 10 organised dental outreaches over one year period. Monthly statistics showed an average attendance of 26 (52%) males and 24(48%) females. The most common presenting complaint was poor oral hygiene/ gingivitis (55%); followed by toothache (40%); poorly arranged teeth (25%); Missing teeth (20%) Discoloured teeth (10%).

Concerning social life style, 50% of attendees gave a history of chewing kolanut and bitter cola, 10% of attendees gave history of cigarette smoking. The following dental treatment were offered during the community outreaches; Scaling and

Polishing (60%), extraction of teeth (40%); A traumatic restoration of teeth (30%) Denture replacement of missing teeth (20%); Study models (10%); Stain removal(10%); Specialist referrals (25%).

**Conclusion:** Organisation of dental outreaches are ways of engaging with the community and offering people centred oral care .

**Keywords:** Community engagement, Dental Outreach, Underserved Community.

## POSTER THREE

### Multiple Supernumerary Teeth In A Nonsyndromic Adult Patient: A Cbct-based Case Report

Odebiyi OT<sup>a</sup>, Uzamere Eo<sup>b</sup>

<sup>a</sup>Department of Orthodontics, University of Benin

<sup>b</sup>Teaching Hospital, Benin city, Nigeria; University of Benin,

Benin city, Nigeria/Summit Dental clinics, Abuja.

Presenting Author: Dr. Odebiyi Oluwaseyi

Email address: [sheyibiyi@gmail.com](mailto:sheyibiyi@gmail.com)

**Background:** The presence of multiple impacted supernumerary teeth typically raises suspicion of an underlying genetic or syndromic condition. However, in rare cases, this may be present without any identifiable syndrome

and often present diagnostic and management challenges. We report an unusual presentation of multiple hyperodontia and dental anarchy in an adult female without any known familial or systemic syndromes; emphasizing the potential for subclinical or undiagnosed syndromic associations and the diagnostic value of conebeam computed tomography (CBCT).

**Case Presentation:** A 25-year-old female patient who presented with multiple supernumerary teeth in both the maxillary and mandibular arches and had no relevant medical, familial, or syndromic history. Extraoral examination revealed distinct craniofacial features such as hypertelorism and prognathism. Intra-oral examination revealed complex malocclusion pattern with a total of 37 teeth in occlusion, including a retained deciduous canine.

Despite the absence of a known family history or medical diagnosis suggestive of a syndrome, the dental and facial findings pointed towards an underlying, possibly undiagnosed craniofacial disorder. CBCT was utilized to accurately assess the number, position and spatial relationships of the impacted teeth. There was a total of 43 teeth, including 11 supernumeraries dispersed throughout both arches, with varying morphologies and orientations, of which 6 were impacted.

**Conclusion:** Non-syndromic presentations of extensive dental anomalies with craniofacial dysmorphism may represent subclinical or novel conditions. CBCT is essential in the evaluation of such complex cases, and further genetic assessment may be warranted.

**Keywords:** Supernumerary teeth, hyperodontia, CBCT, non-syndromic, malocclusion.

## CASE ONE

### Management of Angles Class 1 Malocclusion with Canine Class 2 Relationship on The Right and Canine Class 1 Relationship on The Left, Protruded Front Teeth, Congenitally Missing Upper Second Premolar.

Adeloye AY, Utomi IL  
Orthodontics Unit, Lagos University Teaching Hospital.  
bimsolowo@gmail.com

**Background:** This case reports the orthodontic management of a 14-year-old female who presented at LUTH with Angles class 1 malocclusion on skeletal pattern 1, with canine class 2 relationship on the right and canine class 1 relationship on the left. This was complicated by increased overjet of 8.5mm on the right and 7mm on the left, increased upper incisal angle, incompetent lips with a Jackson score of 1/0, retained and mobile upper second primary molars, congenitally missing upper second premolars, upper midline shift to the left by 1mm, mild upper and lower anterior crowding and rotations.

**Aim:** To maintain full unit class I molar relationship bilaterally, to achieve class I canine relationship bilaterally, level and align the upper and lower arches to achieve normal overjet and overbite, unravel the mild upper and lower anterior crowding, achieve coincident midlines and derotate the rotated teeth.

**Methods:** Interdisciplinary management with paediatric dentist of the extraction of the retained primary second molars due to mobility. Comprehensive upper and lower fixed orthodontic appliance (preadjusted edgewise) was used with Roth 0.022 prescription brackets.

**Results:** The treatment was completed and outlined objectives were achieved.

**Conclusion:** The objectives were achieved with significant improvement in the patient's profile. Fixed lingual retainers and Essix retainers were used for retention

## CASE TWO

### Management of Angle's Class I Division 1 Malocclusion on Skeletal Pattern 2 Using Functional And Fixed Orthodontic Appliance Therapy

<sup>a,b,c</sup>Idahosa Bridget Uzamere EO Ize-Iyamu IN

<sup>a</sup>Department of Orthodontics, University of Benin Teaching Hospital, Benin city, Nigeria;

<sup>b</sup>University of Benin, Benin City, Nigeria/Summit Dental clinics, Abuja.

<sup>c</sup>University of Benin Teaching Hospital/University of Benin, Benin City, Nigeria

Email: bridgeteki@yahoo.com

**Background:** Early intervention using a combination of functional and fixed appliances in Angle's class II malocclusion on a class 2 skeletal base can effectively guide growth and correct malocclusion.

**Case Presentation:** A 12-year-old male presented with a chief complaint of protruding teeth. Extra-oral examination revealed a convex profile with lip incompetence and a skeletal pattern 2. Intra-orally, he exhibited an overjet of 8 mm, a deep traumatic overbite, bilateral buccal crossbites, and malalignment in both arches. The molar and canine relationships were Class II bilaterally. The patient had a history of relapse following previous removable appliance therapy and a positive family history of similar malocclusion. A diagnosis of Angle's Class II Division 1 malocclusion on skeletal pattern 2, complicated by lip incompetence, deep bite, buccal crossbite, and crowding was made.

**Treatment Objectives:** To establish lip competence, correct the skeletal discrepancy by modifying mandibular growth, achieve Class I molar and canine relationships, and normalize overjet, overbite, and arch alignment.

**Treatment Plan And Outcome:** A non-extraction approach using fixed orthodontic therapy and functional appliance therapy resulted in class I molar and canine relationships with a reduction in overjet to 2mm.

**Conclusion:** Early intervention, growth modification, and appropriate appliance selection were key to achieving a stable, functional, and aesthetic outcome.

## CASE THREE

### A Case of 35-year-old Female with Class III Malocclusion and A Tongue Sucking Habit

Chukwuma, Emmanuel Ifeanyi

iceacema@gmail.com

Department of Child Dental Health, University of Port Harcourt Teaching Hospital, Port Harcourt, Rivers State

**Background:** A case of a 35-year-old female physician who presented to the department of Child Dental Health, University of Port Harcourt Teaching Hospital with complaints that she has never been caught smiling on camera due to the arrangement of her teeth. She was observed to have Angle's class III sub-division left malocclusion on skeletal base pattern III, complicated by crossbite of all anterior teeth, a tongue sucking habit, severe spacing on both arches and a compromise of her lower anterior periodontal tissues. Baseline cephalometric values were SNA 83°, SNB 91°, ANB -8°, UIFP 136° and LIMP 103°.

**Methods:** A comprehensive fixed orthodontic therapy of both arches was done using preadjusted edgewise Roth's 022 slot in addition to a fixed tongue rake on the upper arch. The work up to her management involved the preventive and restorative dentists.

**Results:** At the end of management patient was discharged with class I molar relationship, the anterior crossbites were corrected and all the spaces were effectively closed-up. Cephalometric values at the time of debonding were SNA 85°, SNB 90°, ANB -5°, UIFP 126° and LIMP 85.5°.

**Conclusion:** After 25 months of management, the patient was satisfied with the aesthetic and psychosocial outcomes of management. Retention was done with both fixed and ESSIX retainers on both arches.

## CASE FOUR

### Orthodontic Management of A Patient with Angle's Class III Malocclusion Subdivision Right: A Case Report.

Otaren NJ<sup>a</sup>, Osadiaye HE<sup>b</sup>, Uddin Victor<sup>b</sup>

<sup>a</sup>Department of Orthodontics, University of Benin/University of Benin Teaching Hospital

<sup>b</sup>Department of Orthodontics University of Benin Teaching Hospital

Presenting Author Osadiaye HE

Email: hopeosayi@gmail.com

This case reports the orthodontic treatment of a 24-yearold female patient who presented with angle's class III malocclusion subdivision right and mild anterior segment crowding in both maxillary and mandibular arches with an anterior crossbite, retroclined upper incisors. Orthodontic treatment was done comprehensively using upper and lower fixed orthodontic appliance therapy, non-extraction case with removable posterior bite plane appliance, using the pre-adjusted straight wire technique, Roth 0.22x030 prescription. The aim of the treatment was to achieve normal overbite and overjet, class 1 canine relationship and unravel crowding. Remarkable results were seen after over eight months of treatment. Thus, restoring aesthetic, occlusal and functional properties.

**Keywords:** malocclusion, crossbite, angle's class III

# Pictures from the Conference



# Pictures from the Conference



# Instructions for Authors

West African Journal of Orthodontics is a peer-reviewed journal published by affiliated Orthodontic Groups and Associations in the West African Sub region. The journal gives priority to reports of outstanding clinical and experimental and epidemiological works on malocclusion, dento-facial defects as well as important contributions related to common orthodontic problems in children, adolescents and adults worldwide.

## Submission

Manuscripts and registered letters should be sent to: the Editor, West African Journal of Orthodontics, Department of Child Dental Health, Faculty of Dentistry, College of Health Sciences Obafemi Awolowo University, Ile-Ife, Osun State. Nigeria.

Manuscripts in MS word attachments may also be submitted via Email to [wajoeditorinchief@yahoo.com](mailto:wajoeditorinchief@yahoo.com), in addition to hard copies. Tables, figures and text should be included in the same file if possible. Authors may submit their research works by email only; such manuscripts need not be simultaneously sent by post.

However, photographs and/or figures need to be sent separately as hard copy (under figures and illustrations).

## Acceptance

Manuscripts should meet the following criteria: original material, clear writing, appropriate study methods, valid data, and reasonable conclusions supported by the data, in short, they should contain important information on topic of general orthodontic interest.

## Peer-review Process

All the manuscripts that adhere to its style and Instructions for Authors are referred to peer-review. Some of them are rejected immediately after an inhouse review. The rejection at this stage is due to insufficient originality, serious scientific flaws or absence of message. The remaining articles are sent to at least two reviewers who are experts in the subject. Manuscripts are reviewed with due respect for authors' confidentiality, and the identity of peer reviewers is also kept confidential. A decision is made from 6 to 12

weeks according to the response from reviewers, revision by the author(s) and reappraisal on the revision.

The accepted manuscripts are subjected to editorial revision to comply with the requirements on language and style of the journal. The rejected manuscript is not returned to authors but its copies are kept for 3 months to answer any queries. The copyright of the accepted and published articles is held by the journal and all the published materials cannot be reproduced or published elsewhere, in whole or part, without the written permission from the editor.

## Duplicate Submission

Manuscripts are considered with the understanding that they have not been published previously and are not under consideration by another publication. The author should alert the editor if the work includes subjects about which a previous report has been published. A research paper submitted to this journal should not overlap by more than 10% with the previously published material or work submitted elsewhere, which would be considered as duplicate publication. If in doubt, authors may forward copies of the published work or material submitted elsewhere to this journal for decision making.

## Proofs and Reprints

The corresponding author of the accepted article shall be supplied with the proof. Corrections on the proof should be restricted to errors only and no substantial additions/deletions should be made. No addition or deletion in the names of the authors is permissible at this stage. A copy of the issue carrying the article is supplied free of charge to the authors.

Reprints may be ordered on payment in advance.

## Categories of Articles

Articles can be sent as editorials, original articles, review articles, special communications, brief reports, case reports, letters to editor, commentaries, or for images section.

They are mostly included under Events of Interest free of cost. This journal reserves the right to be selective in publishing these announcements.

### **Preparing Manuscripts**

Manuscripts should be prepared in accordance with the Uniform Requirements for Manuscripts submitted to Biomedical Journals. 2 A summary of technical requirements for preparing the manuscript is provided below:

- Three copies of the manuscript should be submitted.
- Use 1 side of standard size 21.6x27.9 cm A4, white bond paper, with margins of at least 2.5 cm on each side.
- Double-space throughout including title page, abstract, text, acknowledgements, references, tables and figure legends. Start each of these sections (in same order) on a new page, numbered consecutively in the upper right hand corner, beginning with the title page.
- Use at least 12 point font size (Times New Roman or Arial).
- Submit photographs and transparencies in a separate heavy paper envelope (enclosed in cardboard, to prevent bending during mail handling).
- Conventional units are preferred with SI units in parenthesis, if available. The metric system is preferred for the expression of length, area, mass and volume.
- Use nonproprietary names of material rugs, devices and other products.
- All manuscripts should be accompanied by a signed statement by all authors regarding authorship, responsibility, financial disclosure and acknowledgements, as per standard format (Appendix J)[23 1 Those sending their manuscript through email are also required to submit this form by post with original signatures.

Manuscripts not fulfilling the technical requirements shall be returned to the authors without initiating the peer-review process.

### **Title Page**

The page should contain (i) the title of the article: which should be concise but informative (simpler the title the better; preferably it should contain all the key words to help electronic retrieval reliably); (ii) a short

running title of less than 40 characters placed at the foot end of the title page; (iii) initials and surname of each author with the highest academic degree(s) and designation at the time when the work was done; (iv) details of the contribution of each author; (v) name of department(s) and institution(s) to which the work should be attributed; (vi) disclaimers, if any; (vii) name, address, telephone, fax, email address of the corresponding author, (viii) source(s) of support in the form of grants, equipment, drugs or all of these; and (ix) declaration on competing interests.

### **Authorship**

All persons designated as authors should qualify for the authorship. Authorship credit should be based on substantial contributions to (i) concept and design, or acquisition of data, or analysis and interpretation of data; (ii) drafting the article or revising it critically for important intellectual content; and (iii) final approval of the version to be published. Conditions 1, 2 and 3 must all be met. Participation solely in the acquisition of funding or the collection of data does not justify authorship. All such people who contributed to the work but do not satisfy all the conditions should be listed in the acknowledgements.

Authors are responsible for obtaining written permissions from everyone acknowledged by name. One of the authors shall act as guarantor of the paper and he/she should take the responsibility for the integrity of the work as a whole, from its inception to published article.

Authors should provide a description of what each author contributed on the title page. Subsequently, no names can be added or deleted without written permission of the editor. Written consent of authors whose names are being deleted should be obtained.

This journal reserves the right to satisfy itself regarding the specific role of each listed author to justify authorship. All authors must give signed consent to publication (Appendix 1).

### **Competing Interest**

Competing interest for a given manuscript exists when the author has ties to activities that could inappropriately influence his or her judgment, whether or not judgment is in fact affected. Financial relationships with industry for example, through employment, consultancies, stock ownership, honoraria, expert testimony, either directly or through immediate family, are usually considered to be the most important competing interests. However, conflicts can

---

## Original Article

Original articles should report original research relevant to basic and clinical orthodontics including randomized trials, intervention studies, studies of screening and diagnostic tests, cohort studies, cost effectiveness analyses and case control studies. While reporting randomized controlled trials (RCT), authors must attempt to be in conformity with the consolidated standards of reporting trial.

## (CONSORT) statements

Each manuscript should be accompanied with a structured abstract (divided into background, methods, results and conclusions) in no more than 250 words. Four to five key words to facilitate indexing should be provided in alphabetical order along with the abstract. The text should be divided in sections on introduction, methods, results, discussion and conclusion.

Acknowledgment section may be included where necessary. Number of tables and figures should be limited to the very relevant ones and may be compressed if necessary. The typical text length for such contributions is 2500-3 500 words (excluding title page, abstract, tables, figures, acknowledgments and references).

## Brief Report

Short accounts of original studies are published as brief reports. The text should be divided into sections, i.e., abstract, introduction, methods, results and discussion.

Abstract should be of 100-150 words highlighting the aims, methods and main results along with 3-4 key words.

The text should contain no more than 1500 words, 3 illustrations or tables and up to 20 references, preferably recent publications.

## Review Article

State-of-the-art review articles or systematic, critical assessments of literature are also published. Normally a review article on a subject already published in the West African Journal of Orthodontics is not accepted for a period of 3 years.

The typical length for review articles is 2000-3000 words, excluding tables, figures, and references.

Authors submitting review manuscripts should include a structured abstract of around 200 words describing the need and purpose of review, methods used for selection, extraction and synthesis of data, and main conclusions.

Clinical cases highlighting uncommon malocclusion condition, orthodontic treatment techniques are published as case reports. Single case reports are usually not accepted, unless some new or unusual aspect regarding aetiopathogenesis, diagnosis or management is brought out that adds to the existing body of knowledge. The text should not exceed 1000 words and is divided into sections, i.e., abstract, introduction, case report and discussion. The number of tables/figures should be limited to 2. Ten recent references are acceptable. A maximum of 3 or 1 author is permitted from the principle and each of the associated departments respectively. Thus, case reports from only one investigative department can have a maximum of 3 authors.

## Letter to Editor(s)

Letters commenting upon a recent article in the West African Journal of Orthodontics are welcome.

Such letters should be received within 6 months of the article's publication. At the editorial board's discretion, a letter may be sent to authors! experts for comments and both letter and reply may be published together. Letters may also relate to other topics of interest to orthodontists and others, and/or useful clinical observations. Letters should not be more than 400 words. The number of authors should not exceed 2, including the authors' reply in response to a letter commenting upon an article published in this journal.

## Images Section

A short text of about 150 words depicting the condition with color photographs (vide infra) is needed.

Normally only clinical photographs are accepted but accompanying skiagrams or pathological images could also be considered for publication.

Photographs should be of high quality, clearly identify the condition and preferably add to the existing knowledge.

## Personal Viewpoint

Such articles are published on topical orthodontic issues including social aspects. It is expected that the authors have sufficient credible experience on the subject for giving viewpoints. These should not exceed 1500 words.

## Notes, News and Events of Interest

Announcements for conferences, symposia, meetings or courses may be sent for publication in advance. The announcements should provide title, date(s) and place of the event and contact address, telephone, and email

occur for other reasons, such as personal relationships, academic competition and intellectual passion. If any of the authors have accepted reimbursement for attending symposium, a fee for speaking, fee for organizing educational reach, funds for a member of the staff of consultation fees from an organization that may in: way gain or lose financially from the result of the study, review, editorial or letter, a competing interest would be deemed to exist. If any of the authors had been employed by an organization that may in any way gain or lose financially from the publication, or if any of them hold stocks or shares in such an organization, competing interest would be deemed to exist. If competing interest exists, the author(s) must disclose them while submitting the manuscript.

### **Abstract and Key Words**

The second page should carry an abstract in case of original article (250 words), review article (200 words), brief report (100-150 words), and case report (50 words), respectively. For original article and reviews, the abstract should be structured as detailed earlier. For brief reports, the abstract should state the purpose of the study, basic methodology, main findings (giving specific data and statistical significance) and key conclusion(s). Below the abstract, authors should provide 3-5 key words for indexing; terms from the Medical Subject Headings (MESH) list of Index Medicus should be used. The basic structure of a paper follows the well known acronym IMRAD, which stands for Introduction (what questions was asked), Methods (how was it studied), Results (what was found) and Discussion<sup>4</sup>.

### **Introduction**

The introduction must clearly state the question that the author(s) tried to answer in the study. It may be necessary to briefly review the relevant literature. Only cite those references that are essential to justify the proposed study.

### **Materials and Methods**

The methods section should describe, in a logical sequence, how the study was designed (e.g., how randomization was done), carried out (e.g., how subjects were chosen or excluded, ethical considerations, accurate details of materials used, exact drug dosage and form of treatment, etc.) and data were analyzed (e.g., an estimate of the power of the study, exact test used for statistical analysis, etc.). For standard methods, appropriate references are sufficient, but if standard methods are modified these should be clearly brought out.

Authors should provide complete details of any new methods or apparatus used (manufacturer's name and address in parentheses).

### **Ethics**

When reporting experiments on human subjects, authors should indicate whether the procedures followed were in accordance with the ethical standards of the responsible committee on human experimentation (institutional or regional) and with the Helsinki Declaration of 1964, as revised in 2000.

They should indicate whether the study was approved by the Institutions' Ethical Committee, and whether informed consent was obtained from the study participants. They should not use patients' names, initials, or hospital numbers, especially in illustrative material. This journal reserves the right to reject a manuscript on ethical grounds, on the basis of recommendations of its "Ethical Committee", even if the research has been cleared by the institutional ethical committee. Moreover, when reporting experiments on animals, authors should indicate whether the institutional and national guide for the care and use of laboratory animals was followed.

### **Statistics**

Authors should describe statistical methods with enough detail to enable a knowledgeable reader with access to the original data to verify the reported results. When possible, they meet to quantify findings and present them with appropriate indicators of measurement error or uncertainty (such as confidence intervals). Actual P values are provided rather than stating as just  $<0.05$  or  $>0.05$  etc. References for the design of the study and statistical methods should be to standard works when possible (with pages stated) rather than to papers in which the designs or methods were originally reported. Any general-use computer programs used should be specified and statistical terms, abbreviations, and most symbols be defined.

### **Results**

This section should include only relevant, representative data and not all information collected during the study. Major findings should be presented clearly and concisely. Text, tables, and illustrations should be used sensibly while avoiding repeating in the text all the data depicted in the tables or illustrations and emphasizing or summarizing only important observations. Tables and figures should be restricted to those needed to explain the argument of the paper and to assess its support. It is necessary to cite the tables in the text and type them on separate sheets. It may also be useful to mention what the study did not find.

## Discussion

Discussion ordinarily should not be more than one third of the total length of the manuscript. This section should include a summary of the major findings, their relationship to other similar studies, limitations of methods and implications of these findings in future research. Conclusions should be linked to the goals of the study. Unqualified statements and conclusions which are not completely supported by the data should be avoided. Authors should also refrain from making statements on economic benefits and costs unless their manuscript includes economic data and analyses.

## Acknowledgements

In acknowledgements section, it is suitable to list all contributors who do not meet the criteria for authorship, such as a person who provided purely technical help, writing assistance, or a department head who provided only general support. Financial and material support should also be acknowledged.

Groups of persons who have contributed materially to the paper but whose contributions do not justify authorship may be listed under a heading such as "clinical investigators" or "participating investigators", and their function or contribution should be described, for example, "served as scientific advisers", "critically reviewed the study proposal", "collected data", or "provided and cared for study patients". A written consent is required from all the persons acknowledged, indicating their acceptance for the same.

## Contributions to joint-authorship

In the case of multiple author-ship, authors are expected to state clearly their contributions to the paper being considered for publication in terms of study initiation, design including methodology, data collection, analysis and final write-up. The editorial board reserves the right to remove any author's name if the contribution is insignificant.

## References

References should be numbered consecutively in the order in which they are first mentioned in the text.

References are identified in text, tables, and legends by Arabic numerals in parentheses. References cited only in tables or in legends to figures should be numbered in accordance with the sequence established by the first identification in the text of the particular table or figure.

The titles of journals should be abbreviated according to the style used in Index Medicus. Authors are required not to use abstracts, unpublished observations and personal communications as references. References to papers accepted but not yet published should be designated as "in press"; authors should obtain written permission to cite such papers as well as verification that they have been accepted for publication.

The references must be verified by the author against the original documents. The Uniform Requirements style (the Vancouver style) is based largely on an American National Standards Institute (ANSI) standard style adapted by the NLM for its databases.

## Journal Article

List all authors when 6 or less. When 7 or more, list only first six and add et al. Ngan P, Yiu C, Hu A, Hagg U, Ei SHY, Gunel E. Cephalometric and occlusal changes following maxillary expansion and protraction. *Eur J Orthod* 1998; 20: 237-254.

## Organization as Author

Australian Dental Association Inc. An Australian Schedule of Dental Services and Glossary. 7th edn. Sydney: Australian Dental Association Inc., 1996.

## Complete Book

Department of Health. Shifting the balance of power within the NHS: securing delivery. London: Doll, 2001.

Clayton D, Hills M. Statistical models in epidemiology. Oxford: Oxford University Press, 1993.

Farkas LG. Anthropometry of the Head and Face, 2nd Edn, New York; Raven Press; 1994

Book Chapter Lekholm U, Zarb GA. Patient selection and preparation. In: Branemark P1, Zarb GA, Albrektsson T, editors.

Tissue integrated Prostheses: Osseointegration in Clinical Dentistry, Chicago: Quintessence; 1988,199-209

## Thesis and Dissertation

Yong SJ. Bone mineral density of normal Korean adults. Ph.D. Thesis. Seoul, Korea; 1989 Anozike, AN. Orthodontic treatment needs and its impact on oral health related quality of life in Lagos school children aged 12-16 years. FMCDs. Dissertation. Lagos, Nigeria; 2006

### **Conference Proceedings**

Marshall SJ, Rixon RC, Whiteford DN, Cumming JT. The OrthoForm 3-Dimensional Clinical Facial Imaging System. Proceedings of the 15th IFHE Congress 1998; 15:83-87.

### **Dictionary and Similar References**

Stedman's medical dictionary. 26th ed. Baltimore: Williams & Wilkins; 1995. Apraxia; p.11 9-120. Unpublished accepted material Leshner AI. Molecular mechanism of cocaine addiction. N Eng J Med. In Press 1996.

### **Material from Internet**

World Health Organization, 2002.  
www.who.int/mental-health/prevention/suicide (accessed August 1, 2004).

### **Tables**

Each table should be typed in double-space on a separate sheet of paper. Tables not submitted as photographs must be numbered consecutively (Arabic numerals) in the order of their first citation in the text, with a brief but self explanatory title for each.

Each column should have a short or abbreviated heading. Explanatory matters are placed in footnotes, not in the heading. In footnotes all nonstandard abbreviations that are used in each table should be explained adequately. Statistical measures of variations should be identified such as standard deviation and standard error of the mean. Be sure that each table is cited in the text. If data are used from another published or unpublished source, it is necessary to obtain permission and acknowledge them fully.

### **Figures and Instructions**

Figures should be professionally drawn and photographed; freehand or typewritten lettering is unacceptable. Instead of original drawings, X-ray films, and other material, sharp, glossy, black-and-white photographic prints of high quality are necessary, usually 127x 173 mm (5x7 in) but no larger than 203x254 mm (8x10 in) For color illustrations negatives or positive transparencies are provided, along with color prints. It is preferable to have the photograph in portrait form rather than in landscape form to fit easily into one column. Letters, numbers and symbols in photographs should be clearly legible.

Each figure should have a label pasted on its back indicating the number of the figure, author's name, and an arrow to mark the top and left side of the figure.

It is unacceptable to write on the back of figures or scratch or mark them by using paper clips, and to bend figures or mount them on cardboard. If photographs of individual/people are used, either the subjects must not be identifiable or their pictures must be accompanied by written permission to use the photograph. It is advisable to cover the eyes unless specifically need to be shown. If a figure has been published, the original source should be acknowledged and written permission from the copyright holder be obtained to reproduce the material. Figures should be numbered consecutively (Arabic numerals) according to the order in which they have been first cited in the text.

### **Legends for Illustrations**

Legends for illustrations should be typed or printed out in double-space, starting on a separate page, with Arabic numerals corresponding to the illustrations.

When symbols, arrows, numbers, or letters are used to identify parts of the illustrations, each of them must be identified and explained in the legend. The internal scale should be explained and the method of staining in photomicrographs be identified.

### **Units of Measurement**

Measurements of length, height, weight, and volume should be reported in metric units, i.e., meter(m), gram(g), or liter(l) or their decimal multiples.

Milliliter or deciliter should be expressed as ml or dl.

Red and white blood cell counts are to be expressed as  $63 \times 10^6 / \text{mc l}$  and  $\times 10^6 / \text{mc}$  respectively. Temperatures should be given in degrees Celsius and blood pressures in millimeters of mercury (mmHg). All hematological and clinical chemistry measurements should be reported in the conventional system or in terms of the International System of Units (SI).

### **Abbreviations and symbols**

Only standard abbreviations are used in the text while avoiding abbreviations in the title and abstract.

The full term for which an abbreviation stands should precede its first use in the text unless it is a standard unit of measurement. Year, month, day, hour, minute and second should be abbreviated as yr, mon, d, h, mm, and s in tables respectively.

## References

1. Mother M, Schulz KF, Altman DG, for the CONSORT Group. The CONSORT statement Revised recommendations for improving the quality of reports of parallel group randomize Trials. *Lancet* 2001; 357: 1191-1194. (Also available from: URL: <http://www.consort-statement.org/>). Accessed June 28, 2002.
2. International Committee of Medical Journal Editors. Uniform Requirements for Manuscripts Submitted to Biomedical Journals. *Ann Intern Med* 1997;126:36-47. (Updated October 2001 version Available from: URL: <http://www.icmje.org/>). Accessed June 28,2002.
3. JAMA Instructions for Authors. Available from URL: <http://jama.ama-assn.org/>. Accessed June 28, 2002.
4. Hall GM. Structure of a scientific paper. In: Hall GM, ds. *How to write a paper*. London:BMJ Books, 2000.
5. 52nd WMA General Assembly. World Medical Association Declaration of Helsinki. Ethical principles for medical research involving human subjects. Available from: URL: <http://www.wma.net/>. Accessed June 28,2002.

## Appendix 1: Declaration of Originality and Transfer of Copyright

*(Please download from Nigerian Association of Orthodontists (NAO) website <https://www.nao-ng.org/>)*

This form is to be submitted with the initial copies of the manuscript to: West African Journal of Orthodontics, Department of Child Dental Health, Obafemi Awolowo University Ile-Ife, Osun State. Nigeria Manuscript No. (If known):

The author(s) hereby affirms that the submitted manuscript entitled:

I/We certify that the manuscript represents valid work and that neither this manuscript nor one with substantially similar content under my/our authorship has been published or is being considered for publication elsewhere. For papers with more than I author, we agree to allow the corresponding author to serve as the primary correspondent with the editorial office, to review the edited typescript and proof.

I/We have seen and approved the submitted manuscript. All of us have participated sufficiently in the work to take public responsibility for the contents. All the authors have made substantial contributions to the intellectual content of the paper and fulfill at least 1 condition for each of the 3 categories of contributions: i.e., Category 1 (conception and design, acquisition of data, analysis and interpretation of data), Category 2 (drafting of the manuscript, critical revision of the manuscript for important intellectual content) and Category 3 (final approval of the version to be published).

I/We also certify that all my/our affiliations with or financial involvement with any organization or entity with a financial interest in or financial conflict with the subject matter or materials discussed in the manuscript are completely disclosed on the title page of the manuscript. My/our right to examine, analyze, and publish the data is not infringed upon by any contractual agreement.

I/We certify that all persons who have made substantial contributions to the work reported in this manuscript (e.g., data collection, writing or editing assistance) but who do not fulfill the authorship criteria are named along with their specific contributions in an acknowledgment section in the manuscript. If an acknowledgment section is not included, no other persons have made substantial contributions to this manuscript.

I/We also certify that all persons named in the acknowledgment section have provided written permission to be named.

The author(s) undersigned hereby transfer(s), assign(s), or otherwise convey(s) all copyright ownership, including any and all rights incidental thereto, exclusively to the West African Journal of Orthodontics, in the event that such work is published in the West African Journal of Orthodontics.

Authors name(s) in order of appearance in the manuscript; signatures (date):

